

# Visual field defects in acute optic neuritis

---

Foršek, Ivor

Master's thesis / Diplomski rad

2016

Degree Grantor / Ustanova koja je dodijelila akademski / stručni stupanj: **University of Zagreb, School of Medicine / Sveučilište u Zagrebu, Medicinski fakultet**

Permanent link / Trajna poveznica: <https://um.nsk.hr/um:nbn:hr:105:981456>

Rights / Prava: [In copyright](#)/[Zaštićeno autorskim pravom.](#)

Download date / Datum preuzimanja: **2024-06-26**



Repository / Repozitorij:

[Dr Med - University of Zagreb School of Medicine Digital Repository](#)



**UNIVERSITY OF ZAGREB  
SCHOOL OF MEDICINE**

**IVOR FORSEK**

**VISUAL FIELD DEFECTS IN ACUTE OPTIC  
NEURITIS**

**GRADUATE THESIS**



**Zagreb, 2016**

This graduate thesis was made at KBC Rebro, Department of ophthalmology:

University of Zagreb, School of Medicine. Mentored by Assistant Professor Dr. sc. Tomislav Vidovic

and was submitted for evaluation in the academic year 2015/2016

## **Abbreviations:**

AION: Anterior Ischemic Optic Neuropathy

DLS: Differential Light Sensitivity

DTI: Diffusion Tensor Imaging

ION: Ischemic Optic Neuropathy

IV: Intravenous

LHON: Leber's Hereditary Mitochondrial Optic Neuropathy

MBP: Myelin Basic Protein

MRI: Magnetic Resonance Imaging

MS: Multiple Sclerosis

MTI: Magnetic Transfer Imaging

MTR: Magnetic Transfer Ratio

NMO: Neuromyelitis Optica

ONTT: Optic Neuritis Treatment Trial

ON: Optic Neuritis

RAPD: Relative Afferent Pupillary Defect

SITA: Swedish Interactive Thresholding Algorithm

## VEP: Visual Evoked Potential

### Contents

1. Summary:.....	5
2. Optic Neuritis.....	1
2.1 Classification .....	1
2.2 Epidemiology.....	2
2.3 Pathophysiology .....	2
2.4 Clinical Features .....	4
2.5 Diagnosis .....	5
2.6 Management .....	6
3. The Visual Field.....	7
3.1 Introduction .....	7
3.2 Anatomy and Physiology.....	8
3.3 Assessment .....	10
3.3.1 Confrontation visual field exam .....	10
3.3.2 Perimetry .....	11
3.3.2.1 Algorithms .....	13
3.3.2.2 Swedish Interactive Thresholding Algorithm .....	14
3.3.2.3 Perimetry Variations in Optic Neuritis .....	15
4. Patterns of Vision loss .....	16
4.1 Central Scotoma .....	16
4.2 Cecocentral Scotoma .....	17
4.3 Arcuate Scotoma.....	17
4.4 Altitudinal defects.....	18
4.5 Hemianopic defects .....	19
5. Visual Field Defects in Optic Neuritis.....	20
6 Acknowledgments .....	23
7. Bibliography: .....	24

## 1. Summary:

Optic neuritis is an inflammation of the optic nerve, there are many etiologies however the most frequent is demyelination which is commonly in association with MS. ON is the first feature of MS in about 20% of patients. The presenting symptoms of optic neuritis can be pain on ocular movement, visual field loss, decreased visual acuity, and loss of color vision. Signs that can be seen on ocular and fundoscopic examination are a RAPD and an abnormal appearance of the optic nerve. ON is more common in young adults (20-45 years) and is three times more likely to occur in women than in men. Two phenomena have also been described in ON, the Uhthoff and the Pulfrich. Uhthoff phenomenon is the worsening of vision upon increasing body temperature, and the Pulfrich phenomenon is the false appearance of depth perception in a lateral movement, as in a side-to-side pendulum swing seeming to appear to move in an elliptical manner. These phenomena are related to the slowing of nerve conduction in the affected optic nerve. Many of the clinical findings and comments on treatment plans came from the ONTT carried out from 1988 to 2003 on 454 participants. The results had shown that the most common visual field defect in the affected eye was diffuse visual field loss (48%), followed by altitudinal defects (15%), central or cecocentral scotoma (8.3%), arcuate or double arcuate (4.5%), hemianopic defects (4.2%). Vision tends to return to normal or almost normal without treatment in a couple months, however the ONTT has shown that the most effective treatment method for ON is a course of IV corticosteroids followed by oral corticosteroids as this can lower the risk of developing MS.

Keywords: Optic neuritis, visual field defects, Ophthalmology

## 2. Optic Neuritis

### 2.1 Classification <sup>(1)</sup>

Optic neuritis is a condition that involves primary inflammation of the optic nerve. It is usually associated with an acute, often monocular vision loss with painful eye movement. Optic neuritis can be classified according to its appearance under ophthalmoscope or by its' etiology.

Classification by appearance:

- Retrobulbar neuritis – Initially the optic disc seems normal, this is because the head of the optic nerve is not involved. This is the most frequent type and is often associated with multiple sclerosis.
- Papillitis – The optic disc is hyperemic and edematous. This may be associated with peripapillary flame-shaped hemorrhages. In children this is the most common presentation, but can also be found in adults.
- Neuroretinitis – Includes papillitis together with inflammation of the retinal nerve fibre layer and a macular star figure. This is the least common type.

Classification by etiology:

- Demyelinating – The most common cause
- Parainfectious – It can happen after a vaccination of viral infection
- Infectious – Can be associated with Lyme disease, cat-scratch disease, syphilis, herpes zoster, and cryptococcal meningitis.
- Non-infectious – Due to systemic autoimmune diseases and sarcoidosis.

## **2.2 Epidemiology**

A majority of cases of optic neuritis will occur in women (up to 2/3rds) and in those aged 20-40. (2) Incidence is also increased during spring time in patients with asymptomatic demyelinating lesions. (3) Geography also has an influence on the incidence of ON, as it is more frequent at higher latitudes (North America, Western Europe and Scandinavia) and less frequent in areas around the equator (4)

## **2.3 Pathophysiology**

ON is strongly associated with MS and their pathophysiology is quite similar. It has been shown that inflammation with lymphocytic infiltration of the leptomeninges and perivascular spaces is one of the first pathologic signs in MS. Akin to these findings, perivascular inflammation in the retina can also be seen in ON. Since the retina is an anatomical site that does not contain oligodendrocytes and myelin, the existence of these lesions and perivascular inflammation has advanced a theory which proposes that vascular changes could be a leading event in demyelinating disorders such as ON and MS. The effects of inflammation are responsible for demyelination and may occur at any point of the afferent visual system. Macrophages are responsible for demyelination as they strip away the myelin surrounding the nerve. Demyelination can occur as a full-thickness lesion involving a few centimeters of the nerve, and it can also be diffuse and reserved in its distribution. The result of demyelination is a defective ability of the nerve to propagate action potentials, which can slow down or stop conduction. This can be



measured with VEP, it has been found that delayed latency is highly correlated with demyelination in ON. Demyelinated axons are very sensitive to changes in their environment and this feature is a probable cause for some of the phenomena associated with ON. Uhthoff had noticed that some patients with MS had presented with reversible visual blurring after exercise, it is thought that this is the result of increased body temperature affecting the heat sensitive nerves and slowing conduction. Another phenomenon is known as Moore's lightning streak whereby patients experience flashes of light upon moving their eyes or hearing certain sounds, this is explained by the increased excitability of the demyelinated axons.(5) Disorders of ocular motor system are frequently the initial sign of multiple sclerosis and occur as its presenting sign weeks, month, or years before other neurologic symptoms and signs develop.(6)

## 2.4 Clinical Features

The diagnosis of acute demyelinating optic neuritis can be made clinically by using physical examination techniques and history taking. The most common symptoms were acute vision loss and eye pain. In about 90% of patients vision loss was monocular; binocular vision loss is more common in children and can present simultaneously or in rapid succession.(7) Loss of vision usually progresses over a time period of hours to days with a peak in one or two weeks.

Worsening beyond one week or failure of recovery within 4 weeks should raise suspicion for other diagnoses. (8) Visual acuity can range from 20/20 to almost no light perception. Eye pain occurred in 92% of patients in the ONTT, it coincided with the loss of vision and mended jointly.

(2) An afferent pupillary defect can be appreciated if one eye is healthy and uninvolved in the disease. This can be examined by performing the swinging light test and demonstrates a diminished pupillary response to light in the affected eye. Another frequent symptom is visual field loss, the most typical type thought to be a central scotoma(9). Other kinds of visual loss can be seen, including diffuse defects (i.e. generalized depression of the entire central 30 degrees of the visual field) and focal defects (10). Up to 66% of patients can have visual field defects without subjective signs of impaired vision(11). Color vision (particularly red) was affected and over 88% of patients had abnormalities on Ishihara plate testing of the affected eye. On fundoscopic examination 2/3<sup>rd</sup>s of patients had a normal appearing optic disc, which is consistent with retrobulbar optic neuritis. The other third of optic neuritis patients had a swollen (papillitis), hyperemic disk. This was also accompanied by blurring of disk margins and venous distension. Hemorrhages are uncommon, and if found can point to a diagnosis of anterior ischemic optic neuropathy. (2)

## 2.5 Diagnosis

A thorough physical examination and history are essential in diagnosing optic neuritis, an MRI scan can be used to confirm the diagnosis and assess the risk of developing multiple sclerosis. There are several new MRI techniques such as DTI and MTI which can help us visualize changes in brain tissue of MS patients. MTI assesses the change in magnetization between protons in macromolecules and unbound protons as are found in the extracellular space, we can use this information to obtain the MTR which can hint at the integrity of the structure, MTR is greatly reduced in affected optic nerves. DTI shows us the capabilities of water to diffuse along different axes in anatomical structures. An uncompromised optic nerve will promote water movement along the main axonal axis and impede it perpendicularly, however, in tissues which have lost their integrity such as demyelinated axons, water will diffuse more easily perpendicular to the axonal axis. (5) Almost 95% of affected optic nerves will show abnormal enhancement on MRI, enhancement is not shown on formerly affected nerves or unaffected nerves. (12) Therefore this is a sensitive finding for optic neuritis. Whilst larger areas of nerve enhancement and canal involvement are associated with worse starting vision, the recovery of vision was similar regardless of size of enhancement or location. (13). Retinal imaging can also be helpful in the diagnosis of ON, there is evidence that thinning of the retinal nerve fiber layer is a feature of early MS and follows ON.

## 2.6 Management

The ONTT has provided us with valuable information on the treatment and long-term outcomes of acute optic neuritis. They followed 454 patients from 1988 until 2006 and compared the effects of different treatments. The patients were randomly divided and placed into three different treatment groups. The first group received oral prednisolone for 14 days at a dose of 1 mg/kg/d followed by 3 days of a tapering dose. The second group received intravenous methylprednisolone for three days at a dose of 250mg every 6 hours followed by 11 days of oral prednisolone at a dose of 1 mg/kg/d. The final group received oral placebo for 14 days. The results of the study had shown that the group which had received intravenous steroid treatment had a faster vision recovery rate during the first month compared with the other treatment groups. IV steroid treatment had an effective but short-term benefit in contrast sensitivity; color vision and visual field at the 6 month follow up. At the 1-year follow up there wasn't any statistically significant change in visual function between the treatment groups. IV steroid treatment also conferred another benefit; they reduced the risk of developing MS. At the 2-year follow up only 8% of patients from the IV+oral steroid treatment group had MS, compared with 18% in the placebo group and 16% in the oral group. Patients treated only with oral steroids had double the risk of recurrent optic neuritis, 30% of patients in the oral steroid treatment group experienced a recurrence within the first 2 years as opposed to only 13% in the IV steroid group and 16% in the placebo group. Therefore, it is contraindicated to treat acute optic neuritis with only oral prednisolone in conventional doses. The results of the trial showed that the most effective treatment plan is to treat with IV and oral steroids; however, it is up to the patient and physician to weigh the pros and cons of faster visual function recovery versus systemic

corticosteroid treatment. It is also possible to use IV dexamethasone instead of IV methylprednisolone as they have both been shown to be effective in treatment with the benefit that dexamethasone is easier to administer and cheaper. (14)

### **3. The Visual Field**

#### **3.1 Introduction**

The visual field is the area of space in which objects can be seen simultaneously while maintaining a steady gaze in one direction. The monocular visual field is composed of two parts, the first being central vision. This includes the inner 30 degrees of vision and central fixation. The second part of the visual field is peripheral vision which covers 75 degrees inferiorly, 60 degrees superiorly, 100 degrees laterally and 60 degrees medially. An upright line splits the visual field into two halves, the medial and the temporal hemifield. There exists a physiological blind spot (scotoma) that corresponds to the location where the optic nerve exits the eye, this is at around 12-17 degrees temporally and 2 degrees inferiorly from central fixation. (15)

## 3.2 Anatomy and Physiology

The extent of the visual field corresponds to the anatomical locations of photoreceptors in the retina. There are two major types of photoreceptors, rods and cones. Cones are responsible for color vision; they are cone-shaped and are placed right under the outer limiting membrane in a single file line. Rods, on the other hand, are responsible for black-and-white vision which gives us the ability to see at night. They are rod-shaped and far more numerous than cones with an estimate of around 120 million rods in the retina compared to approximately 6 million cones. Rods and cones consist of several segments; the inner and outer segments, the cell body and the synaptic terminal. The inner segment contains the cellular machinery necessary for synthesis of opsin molecules. The outer segment is formed by layers of cell membrane discs within a pouch, like a stack of pancakes. This layer contains the pigment rhodopsin (rods) or iodopsin (cones). The cell body contains the nucleus and the synaptic terminal is the site of neurotransmission. The fovea centralis, located in the center of the macula lutea, is a small pit about 1.5mm in diameter. It is densely packed with cones and is responsible for central, high-acuity vision. The center of the retina has a higher proportion of cones, whilst the peripheral retina has a higher proportion of rods. (16)

Photoreceptors contain a visual pigment within the bilipid membranous disks in the outer segment; this pigment is composed of a protein (opsin) and a chromophore which is a Vitamin A derivative (retinal). Retinal is normally bound to opsin in its 11-cis form, however, when it absorbs light it isomerizes to the all-trans form. This starts a cascade of processes which ultimately result in hyperpolarization of the cell membrane and block of glutamate release to second-order neurons which activates the ganglion cells. The axons of ganglion cells form nerve fibers which make their way to the optic disc. There are no photoreceptors in the optic disc, hence the physiologic blind spot in this area. (17)

Coordinates on the visual field are the mirror images of retinal coordinates. If we can bisect the eye into superior and inferior, light that originates below this line would be detected by the photoreceptors located above the line. The same is valid if we divide the eye in half vertically, where light that originates medially to the line would be detected by the lateral photoreceptors and vice versa.

## **3.3 Assessment**

### **3.3.1 Confrontation visual field exam**

We can assess an individual's visual field in a variety of ways; a simple preliminary way to detect visual field defects is the confrontation visual field exam, also known as Donders' test. This involves the physician sitting across from the patient who covers one of his eyes, the patient then looks with the uncovered eye into the physician's eye on the same side. If the left eye is uncovered, he would look into the physician's right eye. The physician then takes his hand and places it out of the visual field, then slowly moves it back until the patient sees it, this has to be repeated in all 4 quadrants. The physician can also place his hand in one quadrant and hold up a certain number of fingers and ask the patient to count them. This examination technique can give a basic estimation of the size of the visual field; however, there are better and more precise ways to systematically test the visual field.



### 3.3.2 Perimetry

Perimetry is one way of systematically investigating a visual field; we perform it by projecting the visual field upon a hemispherical surface. It is essential that any point on this surface is equidistant to the eye, this requires the eye to be positioned in the center of the sphere. The goal is for the patient to be able to discriminate spots of light on an evenly illuminated surface. There are two major types of perimetry, kinetic and static.

Kinetic perimetry involves test objects that are the same size and brightness. They are moved from the outside of the visual field inwards, and the test subject is told to call out when he visualizes the object. This maps out the peripheral vision for the specific stimulus. Using different positions of stimuli we can plot isopters, which are areas of equal differential light sensitivity (DLS). DLS is said to be the threshold of perception of a test object, relative to its background. It is the standard unit of measurement of the visual field. (18)

Static perimetry uses objects that are fixed in place but differ in size and brightness. The size of the stimulus is important because larger spots are more likely to be seen. There are generally 5 different sizes of stimuli that are shown. They were introduced with the goldman perimetry and are numbered in roman numerals from I-V. Each increment in size is 4 times greater than the previous one, the sizes are as follows; (I) 0.25mm<sup>2</sup>, (II) 1mm<sup>2</sup>, (III) 4mm<sup>2</sup>, (IV) 16mm<sup>2</sup>, and (V) 64mm<sup>2</sup>. The brightness of the stimulus is measured in decibels (dB) where 0 dB is the brightest stimulus that an apparatus can create and higher dB values correspond to dimmer stimuli to a maximum of 51dB. Since instruments differ one from

another, the reference is taken to be at 0 dB of each specific instrument. The instrument will attenuate the stimulus until it is no longer visible to the patient; the brightness at which a patient sees the stimulus 50% of the time is known as the threshold. The machine provides a small background light which serves to saturate the rods, thereby allowing testing of the cone photoreceptors. Depending on the instrument the stimulus will be shown for either 0.2 or 0.1 seconds, this allows the patient enough time to visualize the stimulus but is short enough to prevent redirection of gaze towards the stimulus. (19)

There are a few conditions that must be satisfied in order to produce a valid map of the visual field. Firstly, the patient must be able to hold his gaze in a steady position for an extended period of time; hence it is important to have perimeters that are able to perform the test in a reasonable amount of time. Each eye must be tested separately; therefore the non-tested eye must be covered. Refractive errors, presbyopia and astigmatism must be corrected with the use of a lens. To perform the test, the patient places their head on a chinrest and is instructed to stare into a central spot. Stimuli will then be presented upon the hemispherical surface and the patient will be instructed to push a button if they can see it. A non-mobile stimulus is then presented in different areas of the visual field until the threshold values are mapped in each of these areas.

### 3.3.2.1 Algorithms

A variety of algorithms exist that can be used to map the visual field; they differ in their accuracy and the time it takes to perform. They can be subdivided into supratreshold or threshold. A supratreshold algorithm presents a stimulus that is expected to be brighter than threshold at various areas of the visual field and then records them as seen or not seen. This kind of testing is useful for screening, but is too crude to be used for more detailed analysis. Threshold testing involves the presentation of a supratreshold stimulus that gets gradually dimmer in a stepwise fashion until the stimulus is no longer visible; it is then increased until it is once more visible. This is known as a reversal, once this occurs the “steps” may be reduced to more accurately measure the threshold which is defined as the intensity of the last seen stimulus. The standard method that the Octopus perimeter and Humphrey Field Analyzer use is to have increments of 4dB that are reduced to 2dB upon first reversal and continued until second reversal. This sort of testing can be very time consuming and might suffer from decreased patient compliance, thereby affecting the accuracy of the exam. To counter this, more sophisticated algorithms have been developed which use complex mathematics to shorten test times. (20)

### **3.3.2.2 Swedish Interactive Thresholding Algorithm**

One such algorithm is the Swedish interactive thresholding algorithm (SITA). This algorithm does not use a step-wise progression of intensity, but rather by using statistical properties forecasts an estimate of the threshold value. The algorithm estimates the intensity most likely to be seen by an age-matched individual and presents it as the first stimulus. The patient's response to the stimulus causes the algorithm to adapt and present stimuli that are either brighter or dimmer until the threshold is reached, at least one reversal occurs in every test location. SITA also takes into account the threshold values in the immediate vicinity, meaning that if a patient shows threshold values different from expected in a certain area the intensity of the initial stimulus can be modified. Compared with full threshold algorithms SITA is on average 48.8% faster. The mean threshold sensitivity at each point was increased by 1.31 dB with SITA, however at points of lower sensitivity greater differences were seen. Compared to the full threshold algorithm, SITA's sensitivity ranged from 83% to 93.2% in detecting variously defined anomalies. Fields that were found to be normal by full threshold were also found to be normal in SITA in 79% to 96.3% of instances, which depended on what was considered to be the criteria for normality. The conclusion is that SITA offers a great reduction in the time needed to conduct the test, whilst not sacrificing much accuracy.

(20)

### **3.3.2.3 Perimetry Variations in Optic Neuritis**

A study carried out by Wall, M. et al. had shown that there was variability of perimetry results of ON patients at different times on the same day and in between days. They tested 17 patients with ON and compared them to a control group of 10 healthy subjects. All 27 subjects were subjected to five Humphrey 30-2 full threshold tests in one day. This was then repeated in the same period on 5 separate days. The results had shown that patients with ON had great variations in their visual field tests on the same day at different times and at same times on different days. These results were not consistent between patients, and there was even a patient who was observed to have weekly fluctuations between normal and a hemianopic defect and daily fluctuations from a partial quadrant loss to a hemianopic defect. This study has shown that care must be taken when interpreting the visual field results of patients with ON because their visual field results can vary greatly. (21)

## 4. Patterns of Vision loss

### 4.1 Central Scotoma

A central scotoma represents an area of the visual field with moderately or severely decreased visual acuity at the point of central fixation surrounded by normal vision. Usually a central scotoma is brought on by a lesion in the papillomacular bundle or fovea. A variety of causes can be responsible for these lesions including Leber's hereditary mitochondrial optic neuropathy (LHON), toxic-nutritional optic neuropathies (commonly ethambutol, methanol, tobacco, and amiodarone), vascular lesions, multiple sclerosis, glaucoma, and optic neuritis. They are more often unilateral than bilateral, with unilateral scotomas pointing towards retrobulbar neuritis and bilateral scotomas towards toxic-nutritional optic neuropathies. (22)

## **4.2 Cecocentral Scotoma**

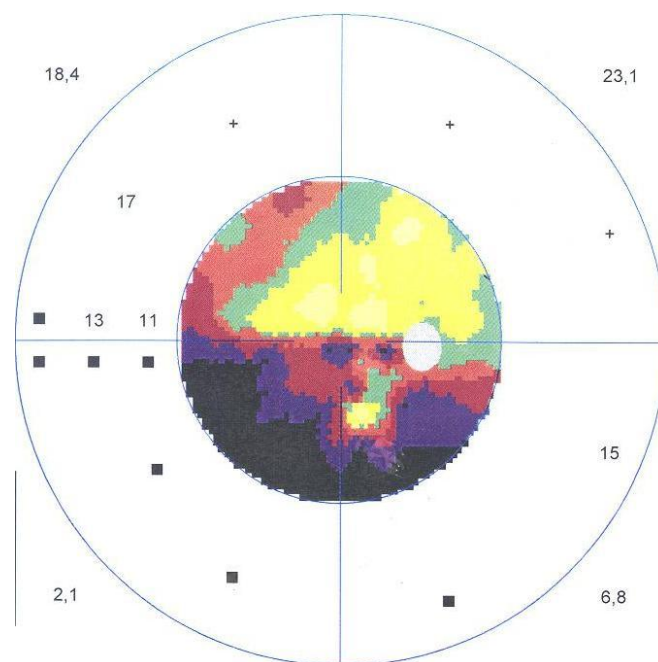
A cecocentral scotoma has a similar pattern of vision loss to a central scotoma, however, there is protraction of vision loss from the point of central fixation towards the physiological blind spot. Unlike a central scotoma the most severe vision loss might not be at the center of the defect, but rather in-between the blind spot and central fixation. The cause is a lesion in the papillomacular bundle which originates in the fovea and makes its way towards the optic disk. Cecocentral scotomas are frequently associated with nutritional and toxic optic neuropathies and commonly present bilaterally. (20) There has been a case outlining a cecocentral scotoma as a presenting sign of subacute bacterial endocarditis in a 67-year old man, thought to be due to microemboli in the blood supply to the optic nerve. (23)

## **4.3 Arcuate Scotoma**

An arcuate scotoma is an arc-shaped visual field defect that occurs near the physiological blind spot and extends further. It is caused by lesions to retinal nerve fibers or to ganglion cells in the superior or inferior arcuate nerve fiber bundles. The most frequent cause of an arcuate scotoma is glaucoma. (24)

## 4.4 Altitudinal defects

An altitudinal defect is an abnormality of the visual field which involves the loss of the entire or a segment of the superior or inferior half of the visual field. This defect can be unilateral or bilateral. A defect can be classified as altitudinal if it is confined within one of the halves of the visual field, once it crosses the horizontal line that bisects the field it can no longer be classified as altitudinal. The underlying mechanism of altitudinal visual field loss is usually caused by optic disk hypoperfusion and consequent infarction. Common causes can be retinal (artery or vein occlusion), an optic nerve lesion (ION, papilledema), or a lesion in the cerebral cortex (temporal or parietal lobe lesion, tumours). (25)

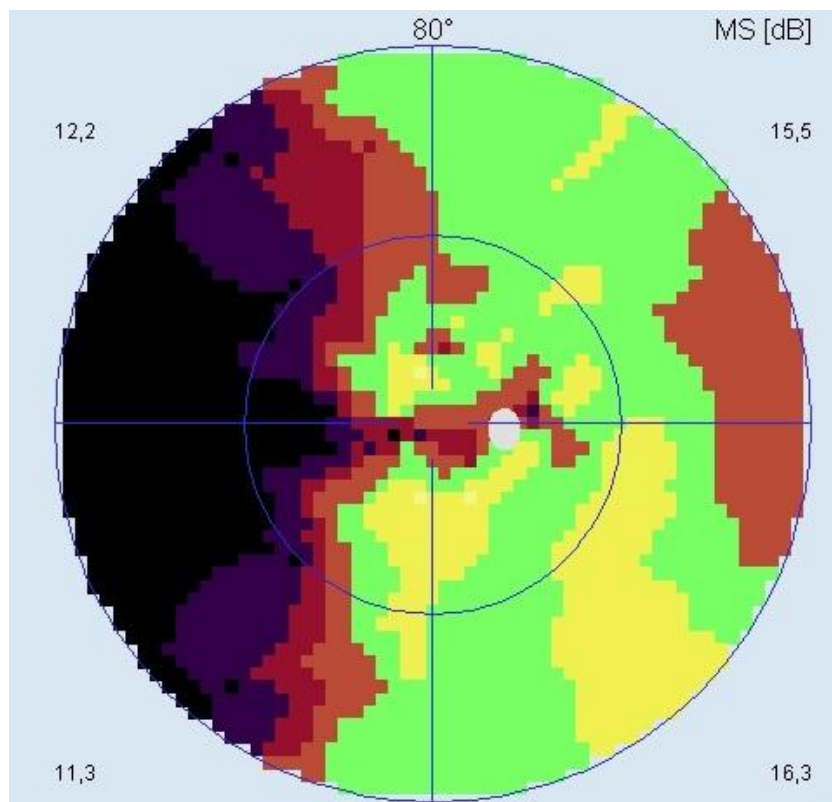


Picture 1: Altitudinal defect



## 4.5 Hemianopic defects

Hemianopic visual field defects involve visual field loss on the left or right of the vertical meridian. It can present unilaterally, but is frequently a bilateral phenomenon. The defects can be partial or complete, where they can involve the entire half of the visual field or just a quadrant. They can also spare the macula and give a few more degrees of central vision, or they can involve the macula and halve central vision. Hemianopic defects can arise from a variety of causes, some of which are; lesions to the optic tract, tumors, trauma and lesions at the visual cortex in the occipital lobe. (26)



Picture 2: Left-sided hemianopia with cecocentral scotoma on right eye

## 5. Visual Field Defects in Optic Neuritis

Most of our knowledge about visual field defects in optic neuritis comes from the Optic Neuritis Treatment Trial (ONTT). During this trial the visual fields were measured at the start and at seven check-ups in the following 6 months, after this they were measured every year for 15 years. Both the affected and the fellow eye were tested. The visual fields were measured by recording the central visual field using a Humphrey Visual Field Analyzer with full-threshold strategy of the central 30-2 with size III targets and 31.5-apostilb background lighting, and by recording the two peripheral isopters with the Goldmann kinetic perimeter. Results showed that at the start of the trial 100% of affected eyes and 69% of fellow eyes exhibited visual field disturbances. The most common visual field defect in the affected eye was diffuse visual field loss (48%), followed by altitudinal defects (15%), central or cecocentral scotoma (8.3%), arcuate or double arcuate (4.5%), hemianopic defects (4.2%). Patients who presented with hemianopic visual field defects (13% in the first year) demonstrated more frequent brain magnetic resonance imaging abnormalities in comparison to patients without hemianopic visual field defects. This signaled the evolution of demyelinating lesions and multiple sclerosis. The data from 6-month and 1-year follow-ups showed improvement in affected eyes where at the 6 month follow up 49% of visual fields were abnormal, and at 1 year 44% were abnormal (100% at start). Fellow eyes also showed improvement in visual fields, after six months 33.2% showed abnormal visual fields and almost the same result was seen after 1 year. (9) At the final follow up in 15 years 50.6% of affected and 35.6% of fellow eyes demonstrated abnormalities in visual field testing. The final results after 15 years had shown that diffuse loss was no longer the most common visual field defect as during years 1-15 only 8-10% of patients had diffuse visual field loss.

Localized loss in the nerve fiber bundle (arcuate, partial arcuate, and paracentral) represented the greatest proportion of visual field defects with around 35-40% of patients presenting with these defects. (27) It was found that patients which developed multiple sclerosis had a higher chance of developing visual field defects. 65% of the cohort population completed the trial.

Another study by Nevailanen. J. et al. had taken the visual field results of 99 patients that had been diagnosed with acute ON and found that the most common visual field defect in affected eyes was a central scotoma (41%) followed by nerve fibre bundle defects (29%) and paracentral scotomas (14%). The fellow eyes in monocular ON were found to have normal visual fields in 65% of cases, however, 21% of fellow eyes showed nerve fiber bundle defects and 9% had diffuse visual field loss. This study had differed in that it had used a different type of perimetry, the Tubingen Automated Perimeter, and that it had used different classification of visual field defects. In the ONTT study, visual fields that were depressed over the entire central 30 degree area were classified as diffuse, however in this study they were classified as central. This study also utilized a much greater spatial resolution whereby they tested 191 locations whilst the ONTT study had tested in 76, this resulted in more precise measurement of visual field defects. (28)

The variety of visual field defects that have been described during the ONTT have made it difficult to discern optic neuritis from other optic neuropathies, as most of these defects are shared between many of these similar diseases. It was found, however, that a central scotoma with a sloping border is a very distinctive feature of optic neuritis and can be used to differentiate from AION which commonly presents with an inferior altitudinal defect with a fine border along the horizontal meridian, especially in the nasal periphery. There are certain criteria which must be met in order to successfully obtain the diagnosis. A full examination of the visual field must be done because otherwise a large central scotoma could be mistaken for a diffuse defect and the nasal periphery border can go unnoticed. (9)

## **6 Acknowledgments**

I acknowledge my mentor, Assistant Professor Dr. Sc. Tomislav Vidovic, for all the help he provided during the writing of this graduate thesis and all the literature and images provided.

## 7. Bibliography:

1. Bowling, Brad and Jack J Kanski. 2015. *Kanski's Clinical Ophthalmology*. [Edinburgh]: Elsevier.
2. "The Clinical Profile Of Optic Neuritis". 1991. *Archives Of Ophthalmology* 109 (12): 1673. doi:10.1001/archophth.1991.01080120057025.
3. Meier, D. S., K. E. Balashov, B. Healy, H. L. Weiner, and C. R. G. Guttmann. 2010. "Seasonal Prevalence Of MS Disease Activity". *Neurology* 75 (9): 799-806. doi:10.1212/wnl.0b013e3181f0734c.
4. Percy AK, Nobrega FT, Kurland LT. Optic Neuritis and Multiple Sclerosis: An Epidemiologic Study. *Arch Ophthalmol.* 1972;87(2):135-139. doi:10.1001/archophth.1972.01000020137004.
5. Burton, E., Greenberg, B., & Frohman, E. (2011). Optic neuritis: A mechanistic view. *Pathophysiology*, 18(1), 81-92. <http://dx.doi.org/10.1016/j.pathophys.2010.04.009>
6. Cerovski B, Vidović T, Petricek I, Popović-Suić S, Kordić R, Bojić L, Cerovski J, Kovacević S: Multiple sclerosis and neuro-ophthalmologic manifestations. *Coll Antropol* 2005,29(Suppl 1):153-158.
7. de la Cruz, J. 2006. "Clinical Profile Of Simultaneous Bilateral Optic Neuritis In Adults". *British Journal Of Ophthalmology* 90 (5): 551-554. doi:10.1136/bjo.2005.085399.
8. Balcer, Laura J. 2006. "Optic Neuritis". *New England Journal Of Medicine* 354 (12): 1273-1280. doi:10.1056/nejmcp053247.
9. Gerling, J., J Heinrich Meyer, and Guntram Kommerell. 1998. "Visual Field Defects In Optic Neuritis And Anterior Ischemic Optic Neuropathy: Distinctive Features". *Graefe's Archive For Clinical And Experimental Ophthalmology* 236 (3): 188-192. doi:10.1007/s004170050062.
10. Keltner, John L. 1993. "Baseline Visual Field Profile Of Optic Neuritis". *Archives Of Ophthalmology* 111 (2): 231. doi:10.1001/archophth.1993.01090020085029.
11. T.Vidovic, B.Cerovski, D.H.Vidovic, J.Cerovski, K.Novak-Laus. Inapparent visual field defects in multiple sclerosis patients, *Coll. Antropol.* 29 Suppl 1 (2005) 67-73.
12. Rizzo, J. 2002. "Use Of Magnetic Resonance Imaging To Differentiate Optic Neuritis And Nonarteritic Anterior Ischemic Optic Neuropathy". *Ophthalmology* 109 (9): 1679-1684. doi:10.1016/s0161-6420(02)01148-x.
13. Kupersmith, M. J., T. Alban, B. Zeiffer, and D. Lefton. 2002. "Contrast-Enhanced MRI In Acute Optic Neuritis: Relationship To Visual Performance". *Brain* 125 (4): 812-822. doi:10.1093/brain/awf087.

14. Beck, Roy W., Patricia A. Cleary, Malcolm M. Anderson, John L. Keltner, William T. Shults, David I. Kaufman, and Edward G. Buckley et al. 1992. "A Randomized, Controlled Trial Of Corticosteroids In The Treatment Of Acute Optic Neuritis". *New England Journal Of Medicine* 326 (9): 581-588. doi:10.1056/nejm199202273260901.
15. Spector, Robert. 1990. "Visual Fields". *Butterworths*.  
<http://www.ncbi.nlm.nih.gov/books/NBK220/>.
16. Kolb, Helga. 2012. "Photoreceptors". *University Of Utah Health Sciences Center*. <http://www.ncbi.nlm.nih.gov/books/NBK11522/>.
17. Palczewski, K. 2011. "Chemistry And Biology Of Vision". *Journal Of Biological Chemistry* 287 (3): 1612-1619. doi:10.1074/jbc.r111.301150.
18. U. Schiefer, J. Pätzold, F. Dannheim: Konventionelle Perimetrie. Teil I: Einführung – Grundbegriffe. *Der Ophthalmologe* 2005, 102(6):627-646.
19. "Standard Automated Perimetry - Eyewiki". 2016. *Eyewiki.Aao.Org*.  
[http://eyewiki.aao.org/Standard\\_Automated\\_Perimetry](http://eyewiki.aao.org/Standard_Automated_Perimetry).
20. "Automated Static Perimetry". 2016. *Aao.Org*.  
<http://www.aao.org/bcscsnippetdetail.aspx?id=7d681413-674c-4f69-a630-12ee8d82da35>.
21. Wall, Michael. "Long- And Short-Term Variability Of Automated Perimetry Results In Patients With Optic Neuritis And Healthy Subjects". *Archives of Ophthalmology* 116.1 (1998): 53. Web.
22. Behbehani, Raed. 2007. *Clinical Approach To Optic Neuropathies*. Ebook. 1st ed.
23. Strauss, Samuel Baharestani, Nemiroff, and Strauss. 2011. "Cecocentral Scotoma As The Initial Manifestation Of Subacute Bacterial Endocarditis". *OPHTH*, 287. doi:10.2147/oph.s16237.
24. Kedar, Sachin, Deepta Ghate, and JamesJ Corbett. 2011. "Visual Fields In Neuro- Ophthalmology". *Indian J Ophthalmol* 59 (2): 103. doi:10.4103/0301-4738.77013.
25. Raj, Akash. 2016. *Altitudinal Visual Field Defect*. Ebook. 1st ed. Mumbai: Bombay Ophthalmologists' Association. Accessed April 17.  
<http://www.boamumbai.com/journalpdfs/oct- dec01/altitudfielddefect.PDF>.
26. Walsh, Thomas J. 1997. *Neuro-Ophthalmology*. Baltimore: Williams & Wilkins.

27. Keltner, J. (2010). Visual Field Profile of Optic Neuritis. *Archives Of Ophthalmology*, 128(3), 330. <http://dx.doi.org/10.1001/archophthalmol.2010.16>
  
28. Nevalainen, J., Krapp, E., Paetzold, J., Mildemberger, I., Besch, D., & Vonthein, R. et al. (2008). Visual field defects in acute optic neuritis - distribution of different types of defect pattern, assessed with threshold-related supraliminal perimetry, ensuring high spatial resolution. *Graefes Arch Clin Exp Ophthalmol*, 246(4), 599-607. <http://dx.doi.org/10.1007/s00417-007-0722-2>