

# Chondrocytes Transplantation in Articular Cartilage Regeneration

---

Menaged, Tal

Master's thesis / Diplomski rad

2024

Degree Grantor / Ustanova koja je dodijelila akademski / stručni stupanj: **University of Zagreb, School of Medicine / Sveučilište u Zagrebu, Medicinski fakultet**

Permanent link / Trajna poveznica: <https://um.nsk.hr/um:nbn:hr:105:076101>

Rights / Prava: [In copyright](#) / [Zaštićeno autorskim pravom.](#)

Download date / Datum preuzimanja: **2025-02-07**



Repository / Repozitorij:

[Dr Med - University of Zagreb School of Medicine Digital Repository](#)



**UNIVERSITY OF ZAGREB  
SCHOOL OF MEDICINE**

**Tal Menaged**

**Chondrocytes Transplantation in Articular  
Cartilage Regeneration**

**Graduate thesis**



**Zagreb, 2024.**

This graduate thesis was made at Department of Orthopedic Surgery, School of Medicine, University of Zagreb, and Clinical Hospital Center Zagreb, mentored by the Prof. dr. sc. Mislav Jelić and it was submitted for evaluation in the academic year of 2023/2024.

### List of Abbreviations:

ACI – autologous chondrocyte implantation

ECM – extra cellular matrix

ICRS – international cartilage repair society

PRP – platelet-rich plasma

NBA – national basketball league

OAT – osteochondral autograft transfer

OCA – osteochondral allograft transplantation

MFx – microfracture

HLA – human leukocyte antigen

IFN $\gamma$  – interferon  $\gamma$

MHC - major histocompatibility complex

N-SAID – non-steroidal anti-inflammatory drugs

MRI – magnetic resonance imaging

MOCART - magnetic resonance observation of cartilage repair tissue

MACI - matrix-associated autologous chondrocyte implantation

BMI – body mass index

## Table of Contents:

List of Abbreviations: .....	2
Table of Contents: .....	3
1 SUMMARY .....	4
2 SAŽETAK .....	5
3 INTRODUCTION .....	6
3.1 Chondrocytes.....	6
3.2 Cartilage .....	6
3.3 The Knee Joint.....	6
4 CARTILAGE INJURY.....	7
4.1 Acute Versus Chronic .....	7
4.2 Classification Of Injury .....	8
5 TREATMENT .....	8
5.1 Non-Operative Treatments.....	8
5.2 Operative Treatments .....	9
6 CHONDROCYTE TRANSPLANTATION.....	12
6.1 Background.....	12
6.2 Procedure .....	13
6.3 Advantages Compared To Other Methods .....	14
6.4 Disadvantages To Other Methods.....	15
6.5 Recovery And Rehabilitation .....	16
6.6 First Generation Autologous Chondrocyte Implantation .....	17
6.7 Second Generation Autologous Chondrocyte Implantation .....	19
6.8 Matrix-Induced Autologous Chondrocyte Implantation .....	20
7 ANALYSIS OF LITERATURE .....	21
7.1 Comparison Between Three Generations of ACI .....	21
7.2 Comparing ACI to Different Current Surgical Techniques .....	23
7.3 Long-term Studies of ACI.....	25
8 CONCLUSION.....	28
9 ACKNOWLEDGMENTS.....	29
10 REFERENCES .....	30
11 BIOGRAPHY .....	36

# 1 SUMMARY

---

Chondrocytes transplantation in articular cartilage regeneration combines new and recent surgical and scientific advancements in cell therapy which is used to treat acute or overuse injuries of the articular cartilage. This surgical technique is called Autologous Chondrocyte Implantation (ACI) and has been performed, studied and improved over the last thirty years.

Autologous Chondrocyte Implantation is done by harvesting chondrocytes from a healthy area of the cartilage, then the chondrocytes are cultured in a laboratory, before being implanted again in the area of the injured cartilage. ACI is a surgical procedure that mainly targets the repair and regeneration of the articular cartilage of the knee joint.

This procedure can be performed with three slightly different modifications known as three generations. While first generation includes placing a periosteal cover over the defect area of cartilage to house the autologous chondrocytes, second generation uses a collagen membrane as a cover instead of the periosteal cover from the first generation. The third generation is based on biomaterials in which the autologous chondrocytes are embedded before being implanted to the area of the defect.

ACI is the topic of many studies which try to conclude how does this technique fit in the world of articular cartilage surgery, meaning how does this procedure compete with other different available procedures. First, studies were being done to measure the short and mid-term effectiveness of the surgery while later as the different generations emerged studies focused on challenging them against one another. Finally, and still on-going, ACI is being tested and studied in the long-term post-surgery period, to measure the success and the incidence of osteoarthritis as well as preserved function of the joint.

ACI is an expensive option for the patients and also requires them to be actively and highly involved in the long process of physical therapy and rehabilitation. It was concluded at this point that ACI is an effective technique both in the short and mid-term periods as well as the long-term periods post-surgery. Many of the patients that were studied reported excellent or good outcomes and this is also supported with the data provided by clinical scoring methods and imaging done during this studies

**Keywords:** *Chondrocyte implantation, Cartilage regeneration, Autologous Chondrocyte Implantation (ACI), Articular cartilage regeneration.*

## 2 SAŽETAK

---

Transplantacija hondrocita u regeneraciji zglobne hrskavice kombinira novija kirurška i znanstvena dostignuća u staničnoj terapiji koja se koristi za liječenje akutnih ili kroničnih ozljeda zglobne hrskavice. Ova kirurška tehnika naziva se autologna transplantacija hondrocita (eng. *autologous chondrocyte implantation* – ACI) te se izvodi, proučava i poboljšava posljednjih trideset godina.

Metoda autologne transplantacije hondrocita podrazumijeva uzimanje hondrocita iz zdravog područja hrskavice, njihovo obrađivanje i umnožavanje u laboratoriju te ponovnu implantaciju u područje ozlijeđene hrskavice. Cilj autologne transplantacije hondrocita je oporavak i regeneracija zglobne hrskavice koljena.

Ova se metoda može izvesti s tri različite modifikacije, poznatije kao generacije. Dok prva generacija obuhvaća postavljanje periostalnog presadka preko oštećenog područja hrskavice za smještaj autolognih hondrocita, druga generacija kao presadak koristi kolagenu membranu kao pokrov umjesto periostalnog presadka iz prve generacije. Treća generacija koristi biomaterijale u koje su autologni hondrociti dodani prije implantacije u oštećeno područje.

Mnoge studije pokušavaju uklopiti ACI metodu u svijet kirurgije zglobne hrskavice, odnosno usporediti je s drugim različitim dostupnim postupcima. Prvo su se studije radile kako bi se izmjerila kratkoročna i srednjoročna učinkovitost operacije, dok su se kasnije, s pojavom različitih generacija, studije usredotočile na njihovu međusobnu usporedbu. Još uvijek su u tijeku studije koje testiraju i proučavaju ACI u dugotrajnom postoperativnom razdoblju kako bi se izmjerila uspješnost i učestalost pojave osteoartritisa te očuvala funkcija zgloba. Studije su došle do zaključka da je ACI učinkovita metoda kako u kratkoročnom, tako i u srednjoročnom te dugotrajnom postoperativnom razdoblju.

Uz to što je skupa opcija za pacijente, ACI također zahtijeva od pacijenata da budu aktivno uključeni u dugi proces fizikalne terapije i rehabilitacije. Međutim, mnogi od pacijenata koji su sudjelovali u ispitivanjima pokazuju izvrsne ili dobre ishode, što je također potkrijepljeno podacima dobivenim kliničkim metodama bodovanja i snimanjima učinjenim tijekom ovih studija.

**Ključne riječi:** implantacija hondrocita, regeneracija hrskavice, autologna transplantacija hondrocita (ACI), regeneracija zglobne hrskavice.

## **3 INTRODUCTION**

---

### **3.1 CHONDROCYTES**

Chondrocytes are the cellular components of the cartilage tissue. They develop from chondroblasts and their main function is to produce and maintain the cartilage extracellular matrix (ECM). Chondroblasts which are the main producers of ECM in cartilage mature into chondrocytes when the ECM they have produced surrounds the cells, then the chondrocyte is trapped in the lacunae it formed and is now maturing into chondrocyte. The chondrocytes continue to carry out their function from the lacunae of the ECM. Upon reaching their mature stage the chondrocytes are no longer able of cell division. Apart from their main function of ECM maintenance and production, the chondrocytes play an important role in an individual's early life as they are involved in the process of endochondral ossification of the skeleton. They are essential for the development of the fetal skeletal system, as well as longitudinal bone growth. As a consequence of their primary function the chondrocytes also play an important role in the process of bone and cartilage healing.

### **3.2 CARTILAGE**

Cartilage is a special connective tissue that adapts to the physical stress that is essential for mechanical movement. Cartilage has two cellular components, the previously mentioned chondrocytes, and their predecessors the chondroblasts. We can differentiate three types of cartilage tissues: hyaline cartilage, being the most common of the cartilage tissues, fibrocartilage and elastic cartilage. In this thesis the main focus is on hyaline cartilage and the use of the word cartilage is synonymous with this subtype. Cartilage holds a special feature as that it has no blood vessels therefore the only means of receiving nutrients come from simple diffusion.

The ECM of cartilage is different than in other tissues. It is composed of different types of collagen. It also contains proteoglycan molecules with a side chain of glycosaminoglycans. One example of such molecule is Aggrecan which forms aggregates with hyaluronic acid. These aggregates attract water molecules; this is one of the mechanisms which provide the cartilage with its elastic properties. Also found in the ECM is glycoproteins such as chondronectin. Chondronectin is a molecule which establishes a connection between the ECM and the chondrocytes. Some types of cartilage are surrounded by perichondrium, which is composed of an outer fibrous layer and an inner chondrogenic layer. The outer fibrous layer contains vessels and nerves that supply the cartilage. The cartilage that is not surrounded by the perichondrium layer is surrounded by articular synovial fluid and a subchondral network which supply the cartilage with nutrients. The regenerative properties of cartilage are limited but considered poor compared to other tissues. This is why an injury to cartilage, specifically articular hyaline cartilage are injuries that if not treated cause pain and limit movement of the affected joint for a long time, in some cases even for a lifetime. That is why articular cartilage injuries require some form of intervention.

### **3.3 THE KNEE JOINT**

The knee joint is an important articular joint in the body. It bears weight and allows us to walk and participate in various sports activities. In epidemiological data of cartilage injuries, the knee joint is reported as most affected joint. This epidemiological data paints a picture of how



vulnerable the knee is compared to the other joints on the list with ankle joint in second place. The knee tops this list for multiple facts including its large articular surface that is covered in cartilage, increased body weight heavily affects the knees due to its weight bearing properties, and sedentary lifestyle that lowers the amount of walking and physical exercise that patients receives has potential to cause weak and underdeveloped knees that are prone to injury of any kind.

Another fact to consider is that the knee joint is the injured joint studied in most research papers on the topic of cartilage injuries and chondrocyte transplantation in particular. Therefore, it is acceptable to say that the knee joint is the most important model to study when it comes to cartilage injuries, surgical treatments of those injuries and the rehabilitation protocols if we want to reduce the stress of this injury of patients and society. It is also important to note that by achieving a better prevention and more important treatment method for the knee joint's cartilage injuries we can lower the risk of development and incidence of osteoarthritis due to cartilage injuries.

## **4 CARTILAGE INJURY**

---

### **4.1 ACUTE VERSUS CHRONIC**

Cartilage injury can be classified according to the duration on the injury: acute or chronic (or overuse injury). Chondral injuries pose a significant issue because of the limited regeneration potential of chondrocytes. Another reason for concern is the avascularity of cartilage tissue, which by itself poses a difficult challenge when it comes to tissue healing. The long term risk of cartilage injury is the development of osteoarthritis of the affected joint. The severity of cartilage injuries is determined by the depth of involvement of the injury, the deeper the insult to the surrounding structures, the higher the severity of the injury. Evaluation of the severity is also based upon the continuity of the cartilage overlaying the injury site. For instance, if the injury to the cartilage crosses the entire depth of the cartilage and reaches the subchondral bone the injury is considered severe. This implies that the prognosis is poorer as well as recovery time from surgery to be longer (1).

Acute cartilage injury typically involves mechanical force to the joint. This may be associated both with accompanying ligament and bone damage. Typical acute injuries occur during sport activities, with a suggested prevalence of around 36% of acute cartilage injuries involving the knee in athletes with acute cartilage injury (2), (3). The common symptoms of acute cartilage injury vary depending on the location, severity and time passed since the injury, and they include: swelling, pain, decreased range on motion of the involved joint with accompanying stiffness and instability of the joint.

Chronic or overuse cartilage injury include similar symptoms and evolve over time as repeated insults inflict the affected joint causing more damage to the cartilage over time. These injuries can occur after acute injuries as re-injuries or as accumulation of sub-clinical damage due to overuse, hence their given name as this implies the most common way to get the injury. These type on injuries are also common with athletes as are the acute injuries. The symptoms are similar to acute injury as well as the increased risk to develop osteoarthritis of the involved joint.

An important symptom that requires more attention is the “locking” or sometimes mentioned as “catching” of the joint. This is also referred to as mechanical symptoms and can be the result of a free flap of hyaline cartilage or an unstable tear to the cartilage. It can also be caused by a detached loose body such as bone fragment. These symptoms are not always present and will show as limited range of motion for example it can show as limited extension of the knee joint. Locking requires immediate attention as it requires the orthopedic surgeon to perform emergent arthroscopic reduction of the free flap or object that prevents the joint from moving freely.

## **4.2 CLASSIFICATION OF INJURY**

The classification of cartilage injuries is based on different classification systems. One of the most commonly used system is the International Cartilage Repair Society (ICRS) Classification system. There are 5 grades of severity in this system where 0 is normal cartilage and 4 is classified as Severely Abnormal cartilage. The classification is based on cartilage tissue appearance and graded based on the depth on the injury as mentioned before. An important note to make is that stage 3 which is also named Severely Abnormal is further classified into sub-groups which takes into account the involvement of either more than 50% of the cartilage depth, calcified cartilage or sub-chondral bone. These are classified accordingly as stage 3 sub-groups A-C. Sub-group includes any injury that is classified as group 3 but in addition has formation of blisters on the cartilage.

It is in my mind very important to stress that this classification can indicate whether a patient might require surgery. What the ICRS classification system fails to interpret is that it does not include any information about the patient’s symptoms as even stage 1 injury can cause immense pain can be interpreted differently by different patients and might indicate surgery in one patient due to the pain and how the injury affects day-to-day activities but not in another. Another issue with this system is that it does not take into account the chronicity of the injury. Therefore, a complete history of the injury must be completed with the patient in order to apply the best treatment step for them.

## **5 TREATMENT**

---

### **5.1 NON-OPERATIVE TREATMENTS**

There are plenty of different non-operative treatment modalities for chondral injuries that might be a better option for a select number of patients. The idea is to not operate on the patients who might be at risk from the operation itself, for example by the exposure to anesthesia, or patients that might have a low ICRS classification stage injury. Another reason why not to operate immediately is to see if the patient might benefit from the non-operative treatment. This would be usually done in professional athletes who’s playing season or competitive events might be in jeopardy with an extended recovery time of the surgery. Another important note is that most of the non-operative treatment modalities might and should be used as part of recovery and rehabilitation after surgery.

The non-operative treatments include a rehabilitation program that focuses on muscle strengthening and endurance training. Another modality is weight management as more body weight can aggravate the injury and associated pain. It could also be extremely helpful to

include dietary supplements such as chondroitin or glucosamine. As well as hyaluronic acid injections as those might limit the progression of the injury or help with recovery.

Another non-operative treatment modality that can be used is Platelet-Rich Plasma (PRP) injections. PRP injection have been recently advocated for use for articular cartilage injuries (4). These injections contain a high concentrations of growth factors derived from the platelets that help to manage inflammation and pain that is associated with articular cartilage injuries. Although this treatment holds very high hopes more research is needed specially to figure out its role in prevention of re-injuries. On that note, another treatment that is gaining popularity with patients who don't wish to go under the knife is mesenchymal stem cell injections. As with any new treatment options this too requires the science to back up the efficacy of this modality.

## **5.2 OPERATIVE TREATMENTS**

In this section I will discuss into some detail the operative treatments for chondral and articular cartilage injury. The topic of this thesis is one of these operative treatments so therefore, I will just mention it in this section, as it will be discussed into much details in later chapters.

### **5.2.1 Indications for Surgery**

An operation for cartilage injury is not suitable for every patient but when it is indicated, it offers the best outcomes compared to non-operative procedures. The indications for the surgical treatments are (5):

- A symptomatic articular cartilage flap or a free fragment inside the joint space. As mentioned earlier in section 6.1 this symptom represents the “locking joint” symptom. When a patient presents with this symptom it at most requires arthroscopy to remove the flap or fragment in order to restore the full range of motion of the joint.
- A large articular defect. This refers to a large surface area that is affected by the injury. Different sizes of defects indicate for different surgical methods for a better outcome.
- Accompanying ligament or meniscal injuries. An extensive injury that also involves other joint structures is considered more severe and requires immediate surgical attention.
- Symptoms persist after a course of non-operative treatment. If a non-operative treatment was initiated but failed to provide results for the patient, it is considered as an indication for surgery.

### **5.2.2 Surgical Techniques**

As with many injuries and diseases, in the surgery world there are many different ways to solve a problem. With cartilage injuries it is no different. It is important to consult with the patient for their goals with the surgery and to choose the best method that suits the injury and the patient. There are three different approaches to cartilage surgery. These techniques will be further discussed in the following sub-chapters.

### **5.2.3 Palliative**

Palliative surgery refers to the arthroscopic debridement, removal and smoothing of cartilage flaps and free fragments which may cause mechanical symptoms, also known as “locking joint”. These techniques are fast, require less recovery time and provide temporary relief of pain to the patient. On the other hand, temporary pain relief is not a desired outcome for most patients as I would assume to consider that the patients would prefer to end the pain completely rather than have a temporary relief. Also palliative surgery doesn't offer any form of promotion of cartilage

repair. This surgery technique is mainly used in two ways first as part of a two stage surgical treatment, meaning that first the patient will undergo a palliative surgery to remove any free fragment or loose flaps that were caused by the injury. This is done in order to relieve the mechanical symptoms. And then, the patient will undergo another surgery, now in order to promote cartilage regeneration and recovery of the lost cartilage tissue. Note that these two stage surgeries can be performed in short succession in majority of patients.

The other use of palliative surgery is when the cartilage injury is not very severe (stage 1-2 on the ICRS scale for example). By doing this surgery the patient is relatively able to go back to their day-to-day activities in relatively short time without the need for extensive recovery. This might also be the solution when the target patient is of an elderly age and would just prefer the reduction of pain. Of course the increased risk of osteoarthritis is still higher compared to an uninjured joint, some of the elderly population would prefer this over an extensive and demanding rehabilitation protocol with longer hospital stay.

#### **5.2.4 Reparative**

Reparative surgical treatment is an arthroscopic surgical technique used in cartilage repair. It involves bone marrow cells by connecting the underlying subchondral bone through drilling of channels. This technique is sometime referred to as microfracture. The operation utilizes a small awl which is used by hammering to create small fractures that connect the bone marrow to the exposed intra-articular environment. Once the connection is made, the pluripotent bone marrow stem cells are able to migrate into the joint space, differentiate into chondrocyte-like cells and promote regeneration. However, it has been shown that the cartilage that was created by this method is not hyaline cartilage but rather fibrocartilage. This technique offers good short term success; it has been shown by long-term studies that there are diminishing qualities to the joint with this surgery (6). One theory suggests that the fibrocartilage is not durable enough for the demands, it is important to note that these demands refers to the studies done with professional athletes as these demands are higher than those of the general population (7).

This surgical technique was created in the late 80s to early 90s and made big and controversial headlines in the National Basketball League (NBA) in the United States. as a few high profile players underwent this procedure. At first the results were good and players were able to return to competition and regained full or near full recovery, and showed a return to their previous abilities. The outcomes of some of the players was poor and they were never able to return to their old form causing them to be forced to early retirement and the loss of their playing contracts (8). The highest profile case of this surgery being performed in the NBA was that of the player Amar'e Stoudemire in 2005, then a young basketball player playing in the team Phoenix Suns underwent microfracture surgery. Stoudemire's surgery was successful despite an early setback he suffered shortly after his return to competition. Microfracture might be a good option for some patients but there must be further discussion about the patient's return to any form of athletic or physical activities as this surgery shown not to have the best results over time and might require a repetition of surgery on the joint.

#### **5.2.5 Restorative**

The aim of restorative techniques is to transfer or grow new articular cartilage into the area of the injury in the joint. This surgical technique includes a few different methods, some of these methods have been studied and repeated plenty of times while some are newer techniques still require more studies and are in the process of being accepted into practice. With that being said

some of these methods have proven to have better outcomes than microfracture in athletes, pediatric patients and general population (9-11).

Osteochondral Autograft Transfer (OAT) is one of the restorative surgical techniques. It is used to fix medium to large defects. This is also an arthroscopic surgical procedure and is performed as follows; first, an area of the damaged cartilage and underlying bone is drilled to a size that fits the size of the graft. This is usually done in a coin shape. Second, a plug of normal cartilage and bone is harvested from a non-weight bearing area of the same joint (usually this surgery is performed on the knee joint). The third stage of the surgery is the fitting of the slightly larger cartilage plug into the coin hole that was created in the first stage of the surgery where the damaged cartilage was. The plug is then pressed into the hole and is fitted into position. This allows the newly implanted plug to grow in the damaged area on the joint. This procedure can be done with one plug or it can be repeated with multiple plugs, which has been described as mosaicplasty. There has been some suggestion that this procedure might damage the donor site and cause increased morbidity, but this has been proven to be wrong when treating smaller areas of defect (less than 4cm<sup>2</sup>) (12). After the completion of the surgery the patient is prescribed a series of rehabilitation and physical therapy to increase muscular and tissue strength of the joint.

Another restorative technique is called Osteochondral Allograft Transplantation (OCA). This is a technique usually used to repair larger defects in the cartilage, and therefore, it is not performed using arthroscopy, but rather it requires open surgery. This method involves transplantation of normal cartilage from a deceased donor. The procedure is done in similar steps to OAT surgery as first the injured or damaged cartilage and some of the underlying bone is removed by the surgeon. Then the area is measured and a similar size is harvested from the deceased donor. Finally, the normal cartilage is transplanted in the area of the defect. The graft can be transplanted as fresh tissue or fresh-frozen. Some precaution is necessary to avoid disease transmission, so therefore the graft is cultured and serologically tested. Since cartilage is immune privileged tissue, rejection of the graft does not occur and there is no need for immunosuppression therapy. OCA is a good option for surgery for the patients with a larger defect where OAT is not considered the best option. Some government regulation and tissue availability might limit the use of fresh osteochondral grafts in this procedure.

Although the good outcomes of restorative procedures, newer techniques are being developed in order to limit the comorbidity associated with OAT and the unavailability of osteochondral graft with OCA, as well as to minimize the risk of graft hypertrophy which is an issue with restorative techniques. Some of the newer techniques involve the use of a porcine membrane for the patch or embedding the chondrocytes in a synthetic matrix. These techniques are relatively new so therefore they are expensive, hence the reason they are not widely used. Also more research is needed to determine long-term outcomes of some of these newer surgical methods.

Restorative surgical methods are a good choice for most patients of average age and regardless of the amount of physical activity they perform on a daily basis. These techniques also require a long physical rehabilitation program and require the patient to abstain from weight bearing activities such as running or climbing a lot of stairs for a long period of time in order for the defect to heal completely. These requirements might be restrictions to some patients as they require them to provide a lot of time and energy into recovery. If these are a problem for a patient, restorative surgery might not be a good choice for them. As mentioned earlier,

Autologous Chondrocyte Implantation (ACI) is another restorative method used, and is the main method used in the topic of this thesis.

## **6 CHONDROCYTE TRANSPLANTATION**

---

### **6.1 BACKGROUND**

The goal of chondrocytes transplantation in regards to cartilage regeneration is simple; to use the body's own normal chondrocytes to induce cartilage regeneration in an injured area of the articular cartilage. The surgical technique called Autologous Chondrocyte Implantation (ACI) offers to do just that. This surgical method was first described in 1994 by orthopedic surgeon and professor at the University of Gothenburg, Mats Brittberg and his team. They suggested the use of the patient's own chondrocytes as a graft will solve some problems associated with the other restorative surgical methods such as OAT and OCA such as morbidity of the donor site in OAT and the increased suspicion that osteochondral allografts used in OCA are in fact immunogenic in vivo as compared to the in vitro assumption. A recent study questions this issue and whether those suspicion are true (13), because if proven that OCA is potentially hazardous and might trigger an immune reaction from the host it would create a large hole in treatment of large injuries and defects of articular cartilage. This could open the door for surgical techniques like ACI into the mainstream of general practice. If ACI is successful at replacing OCA as the treatment of choice for large articular cartilage injuries, it might as well try to replace OAT for smaller injuries which has been associated with donor site morbidity, as mentioned earlier.

Indeed, when considering OCA surgery as safe we must look further into claims that allogenic cartilage is immunogenic. A study of in vitro allogenic chondrocytes showed that when paired with lymphocytes in the same ECM has not promoted any lymphocyte proliferation. And this is because juvenile chondrocytes are less immunogenic than their mature counterpart because of less Human Leukocyte Antigen (HLA) expression. Also, the potential immunosuppressive properties of chondrocytes have been studied and it has been suggested that the chondrocyte expression of B7 receptors act as inhibitory signals to T-cells. Chondromodulin and indoleamine 2,3-dioxygenase which are a T-cell inhibitor and a mediator of immune evasion compounds have also been found on these chondrocytes (14). These different compounds have proven to the researchers that these in vitro allogenic chondrocytes are not immunogenic.

However, juvenile chondrocytes, when exposed to recombinant human interferon  $\gamma$  (IFN $\gamma$ ) show an increased expression of MHC (Major Histocompatibility complex) Class I. This in fact, means that the juvenile chondrocytes are immunogenic when exposed to pro-inflammatory mediators. Which concludes, that in inflammatory conditions for example; a condition in common association with chronic or overuse articular cartilage injuries such as osteoarthritis or other general inflammatory conditions these allogenic juvenile chondrocytes are immunogenic.

Many studies have been shown to have great results with in vivo transplantation of allogenic chondrocytes and have recorded no sign of activation of the immune system after the transplant by the graft. But, some studies have showed certain immune responses such as macrophage and lymphocyte aggregation (15-17). A cause for these can be the different preparations and techniques used in those studies to prevent activation of the immune system. This could be a cause as to why some studies have conflicting outcomes to the same operation in question. With that in mind it could be assumed to say that allogenic chondrocyte transplantation is

controversial (13). It is important to mention that a course of steroidal injection or Non-Steroidal Anti Inflammatory Drug (N-SAID) or other immune-modulator drug regimens have not been tested following an OCA operation as these might solve the immunogenic activation following the operation, or as part of the rehabilitation protocol.

The need for a safe and more available method rose and the idea to harvest a sample of the patient's own healthy chondrocytes also known as an autograft, cultivate them ex-vivo, and then transplant them into the injured articular cartilage. Autologous chondrocyte implantation is the next generation in reparative cartilage surgeries since potentially it is associated with least morbidities or immunogenic activation. It lacks in more research because of the high cost of the procedure but if studied more, better and more efficient ways could develop out of this.

## **6.2 PROCEDURE**

Before undergoing the procedure of ACI, the patient will be evaluated thoroughly by means of extensive physical examination, followed by imaging studies with preference to Magnetic Resonance Imaging (MRI). After those steps an arthroscopic evaluation might also be needed to assess the area of the defect as well as the exact location. Finally, the severity of the defect is estimated based on the finding. If the patient consents to undergoing the surgery and they are found to have a matching criteria to the surgical guidelines, they will be prepared for the operation. Of course, same as in any other operation a pre-operative consultation with an anesthesiologist and cardiologist, if needed, is scheduled to be completed before the operation.

ACI is performed in a few surgical steps. The first as mentioned earlier is a diagnostic arthroscopy to evaluate the severity of the injury. The second step is the harvesting of chondrocytes. This step is done also through the use of arthroscopy. The procedure calls for the harvesting of chondrocytes from a non-weight bearing area of the joint. The sample needs to be of a small and healthy area. After a healthy specimen has been produced by the surgeon, the sample will travel to a specialized laboratory in order to be cultured.

The next step in the procedure is culturing of the chondrocytes from the sample. This step has been changed a lot throughout history and many laboratories still use a different method for isolating and culturing the chondrocytes. This step is extremely important as it determines if there will be enough chondrocytes to manage the injury. Of course, more chondrocytes the better, but this step is also one of the lengthy and costly of the whole procedure. Usually it would take several weeks to produce a good number of cultured chondrocytes although this number varies a lot.

The most advanced culturing methods include the use of at least two different cell types. The medium that the cells are cultured in also varies but regardless it requires a high level of tissue engineering in order to produce the best most accurate reproduction of the complicated tissue structure. This is done by choosing the best biomimetic scaffolding for the culture. These biological ex-vivo systems are also a good tool for studying this subject without the need for in vivo animal studies. The more complex the system, and the more it represents the actual living tissue, the better the results. Experts are sure that our further understanding of articular cartilage regeneration is hidden in the understanding of these ex-vivo models and specifically understanding the chondrocyte to sub-chondral bone signaling (18).

After the process of culturing the chondrocytes has been completed with good results the next step of the procedure can begin. In this step the patient is back on the operating table. The goal

of this step is to prepare the joint for the chondrocyte implantation. It is done the same as other regenerative procedures accomplish this step, by removing the area of the defect. Usually this is done by open surgery rather than by the use of arthroscopy. During this step the cartilage defect is removed and the surgeon prepares the joint by removal of any unhealthy or damaged tissue in order to create a stable area for implantation.

The next step of the process is the implantation of chondrocytes into the area where the defect was. The implantation is done with the use of biological scaffolding which provides as a supportive structure for the implanted cells. This scaffolding also helps to ease the integration of the new cells into the surrounding healthy cartilage. This step is usually done in the same operation as the previous step as there is a need to keep the implantation area clean and ready for the new cultured chondrocytes.

Immediately following the previous step, the patient is started on post-operative rehabilitation protocol. This protocol is very well patient centered as different patients have different lifestyle and physical abilities. But regardless of this fact the protocol includes for all patients the restriction on weight bearing exercises such as running and jumping for around six months post operation. The protocol focuses on exercises to restore full range of motion and strength of muscle and all other joint structures. Physical therapy is a staple in these rehabilitation protocols and involves a session with a physical therapist multiple times a week.

Throughout the rehabilitation protocol the patient has regular follow-up visits with the surgeon. These sessions are essential to evaluate the progression of the patient back to full health and to make adjustments if needed. During the follow-up visits it is usually required of the patient to undergo more imaging studies, in order to accurately assess the status of the implanted chondrocytes in the repaired cartilage. Follow-up visits usually take place until the patient has fully recovered and has completed successfully their rehabilitation protocol. This might take more than a year depending of the patient's condition and healing rate as well as other personal factors.

### **6.3 ADVANTAGES COMPARED TO OTHER METHODS**

The advantages of ACI to other surgical methods are many. First major advantage is the use of the patient's own chondrocytes as the source of the graft. This theoretically ensures that the autograft is non-immunogenic since the cells in the graft contain the same genetic material as the host. It is an important issue to mention since recent studies have shown that the allografts used in the OCA method has the potential to cause immune activation and immune cells aggregation (15-17). Although this studies are recent and thus have no meta-analysis comparison it is safe to say that the OCA method is controversial in that regard.

Another advantage that is obvious when compared to OAT is the issue with donor site morbidity. According to a study that determined the occurrence of donor site morbidity after OAT surgery, a considerable amount of patients following the OAT surgery were found to have some morbidity of the donor site (19). A different study aimed at figuring out the rates for donor site joint morbidity in the ACI surgery has found that ACI is not associated with significant donor site joint morbidity for the period of five years post-operation, supported by data shown in *Table 1*, but it strongly advises to carefully assess which donor site the surgeon should choose. As the study advises that the knee function would be affected in the long term following the operation if it was chosen as a donor site (20).



Table 1. Lysholm Scores of patients postoperatively, and throughout the study (McCarthy et al. 2016).

	Excellent (95-100%)	Good (84-94%)	Fair (65-83%)	Poor ( $\leq 64\%$ )
Preoperatively	72	17	5.5	5.5
First annual review	42	37	21	-
Latest follow-up	33	22	39	5.5

While ACI shows important advantages to its counterparts in restorative surgical methods of cartilage injury. Its advantage to regenerative surgical methods is clear. The advantage is that in the regenerative microfracture method the regenerated cartilage is fibrocartilage and not articular hyaline cartilage that a weight bearing area of the joint normally has. This obviously impairs function, as discussed earlier. As with ACI the regenerated cartilage is hyaline articular cartilage that resembles the normal tissue. This is an important distinction between the two methods, as it will be smart to consider that patients would not want include a decrease in function as a good sign and outcome of the surgery, especially if they maintain a high volume of physical activities or it is necessary in their occupation.

#### 6.4 DISADVANTAGES TO OTHER METHODS

There are a few disadvantages with ACI as compared to other surgical methods. One of these disadvantages is the lengthy rehabilitation protocol needed after the surgery in order to achieve the best results for the patient. This long rehabilitation process is estimated between 12-18 months per most recommendations with a long period of non-weight bearing on the operated knee. Other factors of the recovery and rehabilitation force the leg to be immobilized for the day following the surgery with no movement at all. This is due to the fact that since it is a cell based therapy it is important to allow the chondrocytes enough time to embed in the tissue. ACI also calls for a period of limited weight bearing and gradual strengthening of the muscles and joint therefore, it requires the patient to use crouches which limits other activities and daily functions.

Another disadvantage with ACI is the cost of the surgery. A study considering these facts found that the 3<sup>rd</sup> generation surgery of ACI costs around 15,000 euros while a microfracture surgery costs around 5,000 euros (21). Obviously these prices are not applicable worldwide as rates in different countries can vary a lot, but the point is there. ACI is a much more expensive surgery, with a three times increase then microfracture. A generous sum of the expenses paid for the surgery will go to the culturing process of the chondrocytes, while one cannot ignore the fact that there are two surgeries that need to be done with ACI which increases the costs as well. A contradicting fact is that ACI is a fairly new surgical technique that is still being studied in multiple universities and hospitals, so participation in a study might have benefits to the patients like a lower cost of the surgery.

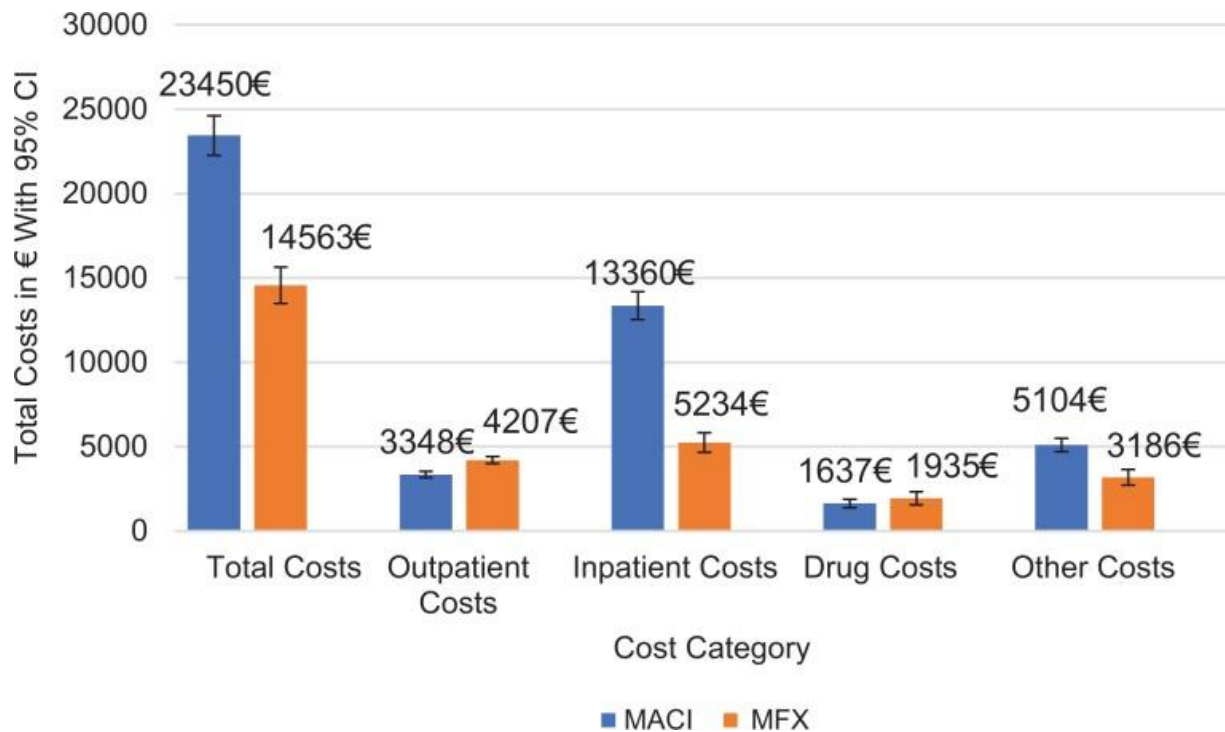


Figure 1. Total cost per surgical method. MACI - matrix-associated autologous chondrocyte implantation, MFX – microfracture (Niemeyer et al. 2019).

The last disadvantage that would be discussed was briefly mention in the last paragraph. ACI has a minimum of two surgeries that are crucial for the procedure. And as a matter of fact these two surgeries must be done a few week or sometimes even months apart, so truthfully there are two different surgical periods that each patient must go through. These include a hospital stay and multiple checkups as well as the use of anesthesia during the operation which some patients might have several problems with. The reason that two surgeries is only the minimum amount needed is because most likely that an evaluation arthroscopy will be done to determine the severity of the injury as well as a follow-up arthroscopy after the surgery and rehabilitation were completed to check if the cartilage has been healed. The increased number of surgeries might turn some patients away from this method, as they might consider a method which includes less steps to achieve a similar outcome, although it might have increased risk further in their future.

## 6.5 RECOVERY AND REHABILITATION

ACI is a complex procedure and requires a thorough recovery and rehabilitation support for the patients. This processes are longer than with different cartilage repair procedures and might take up to 11.6 months (22). The studies on this process of rehabilitation and recovery mainly use professional athletes who are usually younger and in better physical condition, and may require the general untrained and older population more time to return to full function they achieved prior to the surgery.

The physical rehabilitation of a patient post-surgery has proven to be an important factor for achieving better surgical outcomes. Unfortunately, there is no standardized protocol for post-surgical physical rehabilitation of cartilage and osteochondral repair of the knee joint, but there

has been enough evidence to specify the different emphasis and methods for these protocols. The important factors for a successful recovery are; bracing of the joint post-surgery, limited and gradual weight bearing on the joint, early and continuous passive range of motion, and finally the strengthening of the related musculature and joint structures of the knee. Also, there is evidence to suggest that there is a superior outcome for the patients who had accelerated rehabilitation after ACI than those who had delayed rehabilitation post-surgery (23).

## **6.6 FIRST GENERATION AUTOLOGOUS CHONDROCYTE IMPLANTATION**

The first generation of ACI surgery has been performed since the 90s. Since then various studies have been conducted about this type of surgery that offers us a great insight on the surgical procedure. Also enough time has passed since surgeons have been operation with this technique that we are now able to gather important information in the form of long term clinical studies and meta-analysis, which give us better statistical significance of the data that was found in the earlier studies. It is important to understand the results of these studies in the long term since the ultimate goal of the surgery is to restore knee function and lower the risk of osteoarthritis that was present before the surgery.

The first study to feature has done just that, long term clinical observation of patients who went through first generation ACI during the years 1997-2004. The clinical observation of these patients was done using imaging studies, MRI, and various other scales and scores to evaluate the integrity of the joint. These scores are Lysholm score, Tegner activity score, subjective International Knee Documentation Committee score, an independent numerical evaluation scale and the Magnetic Resonance Observation of Cartilage Repair Tissue (MOCART) score. Overall the researchers studied 23 patients with a mean age of 30.5 years for between 7 to 14 years (mean average of 9.9 years) after the surgery. MRI was done postoperatively and at the final evaluation of the patient.

The outcomes of the study show improvement in all of the clinical outcomes, even after 14 years post-operation (24). They also noticed that in the younger patients the outcomes were better, but this might be because of the smaller defects they had compared to the older patients. They also recorded a 52.3% of cases where the cartilage defect was completely healed per MRI imaging. They concluded that first generation ACI is an effective treatment for full-thickness large chondral and osteochondral defects of the knee joint.

A 2009 study biopsied patients who underwent first generation ACI operation alone or combined with mosaicplasty on the knee joint, in order to get a clearer image of the spectrum of different collagen fibers that were present in the regenerated cartilage. By doing that they could determine what type of cartilage the autologous chondrocytes were able to produce. The study was performed on 58 patients of which eight were healthy control. Although using patients who underwent mosaicplasty should show us mixed results they are one of the only studies from that time that performed a histological and qualitative study on the tissue samples. They also provided relatively long term finding since they acquired the samples between 8-60 months post operation.

The results of the study showed the following; the thickness of the repaired cartilage was 2.89 mm with a deviation of 1.5 with good integration of the basal structures of the tissue (repair cartilage, calcified cartilage and subchondral bone). The biopsies showed that 65% of the collagen type that was found was that of fibrocartilage (type I and type IIa procollagen). They

also noticed that 15% of the biopsies were hyaline cartilage (type II collagen), another 17% were mixed type (25). These results might discourage some as it shows a clear dominance of fibrocartilage rather than the desired hyaline cartilage, but it is important to mention that the type II collagen and type IIa procollagen were usually found in the lower areas of the biopsies, and that in biopsies that were done 30-60 months post-operation show mostly collagen type II. This finding actually supports the hypothesis of the research that as time goes there is increase of type IIa procollagen from 2% post-operation to around 30% 5 years after treatment. This means that hyaline cartilage does form over time but requires a few years to regenerate and mature.

A different study that was conducted a year before the last one showed an interesting conclusion. The study was conducted on eight patients with an average age of 50 years who needed a high tibial osteotomy due to tibial chondral defects in a varus knee. The researchers added an arthroscopic first generation ACI procedure to the high tibial osteotomy to try to achieve a better consensus on the ideal approach to patients with medial tibial plateau and varus malalignment of the knee. Their results were the following; after the operation the patients scored an improvement on the Lysholm score, Tegner score and on a subjective knee evaluation form (26).

The results from this study showed us that first generation ACI could be used in addition to a varus knee with chondral defect correction operation. This showed a lot of promise of the first generation ACI since it could also be used to treat a different kind of problem as the ones studied in this research. Although this study design is a cohort retrospective study and features no control group, it gives us enough information on the success of first generation ACI. Another anecdote is the use of an older population in this study shows potential breakthrough in their treatment. Since it is important to remember that the older the patient is the more recovery time they will need.

A case series study from the same year attempted to achieve a similar result. The researchers studied patient who underwent first generation ACI in order to repair a large defect who are older than 45 years. They wanted to measure the levels of success of first generation ACI in an older population as they hypothesized that results would be different than with a younger population. This case series included 56 patients, 36 males and 20 females. Their average age was 48.6 with a mean transplant size of an area of 4.7 cm<sup>2</sup>. The results of the study were good as 72% of patients described themselves as in good or excellent condition, with 78% of the patient reported an improvement and 81% of all studied patient would choose to repeat ACI if they had another choice. Overall, the study showed comparable results with a younger population with the need of repeated arthroscopies being similar as well (27).

The results of these different researches and many more showed surgeons and as well as other researchers that the use of first generation ACI were good, and most important most patients that were mentioned in these studied reported of an improvement in their condition. With the longer term studies that followed the patients for a substantial amount of time it was clear to see that the majority of the patients had a good outcome and would choose to do ACI again if they had a chance. It would be wise to suggest that the first generation of ACI was successful as it introduced the scientific world to a new possibility of regeneration of hyaline cartilage that was considered fiction only a few years prior.

As technology progressed a newer surgical technique for implantation of autologous chondrocytes was developed. Compared with the first generation ACI which used a periosteal

flap suturing over the defect, the second generation of ACI surgical techniques made use of a collagen membrane that was sutured over the defect and the subsequent suspension of cultured autologous chondrocytes was injected underneath. This new technique was now available for surgeons to perform and for researchers to evaluate and compare to the older first generation technique.

## **6.7 SECOND GENERATION AUTOLOGOUS CHONDROCYTE IMPLANTATION**

The second generation of ACI surgery was tested in plenty of studies, at the time of implementation of the technique some of the concern was around how the treatment would last over a long time. But first studies focused on efficacy of the treatment and the need to identify indications of which patients will be a good fit for ACI rather than another surgical technique.

One study out of Italy in 2007 tried to establish some clear indication criteria for the use of second generation ACI for a specific patient. The researchers studied 70 patients that were treated by arthroscopic second generation ACI after a range of 3-4 years post-surgery. It is important to mention that some of these patients were treated for with isolated chondral injuries (31 patients) and the rest had other associated conditions (23 patients with ligament damage, 28 patients with various meniscal injuries and 1 patient with varus knee). Regardless of whether they had an associated condition or an isolated chondral injury, all patients were treated with the same chondral harvesting, as one would undergo with an isolated chondral injury if they were treated with ACI.

According to the study's conclusion, a significant statistical improvement was shown at around 2 years post-surgery. A second look arthroscopy that was done of a select number of patients (15 in total) has shown a complete coverage of the defected area in 12 of the cases. They also specify that the cartilage that was formed over the lesions is indeed hyaline-like cartilage as expected from ACI. The study also emphasizes that the results were better with the younger population and those who had traumatic injuries, also they report better outcomes with the patients who had good physical shape prior to the surgery (28). There are many important notes to take from this research as it, apart from showing promising results with a second look arthroscopy that younger patients have better results from the surgery, also with the well trained population, as this is a modifiable factor compared to age.

Another European study, this time from Germany, from the same year as the previous one, had similar study design. They tested the efficacy of second generation ACI in both short and mid-term follow-ups of 40 patients in the study pool. The technique that was used in the surgery was indeed second generation ACI but it used a special bio-degradable three dimensional gel-polymer scaffold in which the harvested chondrocytes were embedded in. This scaffold is called BioSeed-C. Another thing to note is that the patients in the study were all either those who suffered a traumatic injury or had a focal osteoarthritis lesion.

They researchers used a second look biopsy as their tools to evaluate the patients as well as the usual different scoring systems already mentioned in the other studies that were brought into discussion in this thesis. The study reports a significant improvement in overall evaluated scores at short-term post-surgery (one year), and at mid-term post-surgery (two years). In addition, the histological staining of the biopsies showed good integration of the BioSeed-C and as well the formation of what they call cartilaginous repair tissue (29). The study confirms that

the use of BioSeed-C as part of second generation ACI is an effective and efficient way to treat post-traumatic and focal osteoarthritic cartilaginous lesion of the knee.

A study from the following year used a fibrin-hyaluronan matrix as a natural scaffold for the cultured autologous chondrocytes. This study featured eight patients with chronic symptomatic cartilage defects. These patients were followed by the researchers after a year post-surgery. The results were good; the researchers report an increase in clinical scores as well as the appearance of good filling of the defect with MRI (30). Importantly, the researcher reported three incidences of effusion following the surgery but otherwise they had no adverse effects to report.

With the results in these studies and others, we can say that the story of ACI is becoming clearer. It is being tested in various techniques and all around the world with good results. The missing piece would still be the long-term outcomes of ACI. Before this could be reported, a newer version of ACI was invented and started to be tested around the world.

## **6.8 MATRIX-INDUCED AUTOLOGOUS CHONDROCYTE IMPLANTATION**

Even though first and second generation of autologous chondrocyte implantation were showing great results a new surgical technique was described. Although it is the successor of the second generation of ACI it was named Matrix-induced Autologous Chondrocyte Implantation (MACI) or also known as the third generation of ACI. The main idea was to improve on the second generation by removing some of the undesired results of the treatment such as, periosteal hypertrophy, arthrofibrosis and transplant failure. With further advances in technology especially in tissue engineering, allowed the development of a biodegradable tissue which could be used as the medium for the autologous chondrocytes to be embedded in during the implantation. According to research this biodegradable tissues could potentially improve the placement of the autologous chondrocytes as well as enhance the proliferation of the chondrocytes (31).

A research group from Germany published their results on MACI after having treated fourteen patients with isolated patellofemoral cartilage lesions. These procedures were done using a 3D collagen gel called CaReS. This 3D collagen gel was seeded with the autologous chondrocytes that were harvested from the patients before the implantation. The patients were followed-up two years after the surgery.

The results of the study were very good according to the reports. 78.6% of patients reported an excellent or good outcome as well as a significant statistical improvement in the clinical scores that were measured post-operation and after the two-year follow-up of the patients. Specifically, a great improvement in the ICRS score that went from 32.4 post-operation to 67.8 at the two-year follow-up, almost doubling in value only after two years. The study concludes that 3D collagen gel could replace previous generations of conventional ACI therapy although, they also mentioned the need for further long-term studies (32).

A similar study that also used the CaReS 3D collagen gel matrix reported similar findings. They reported on thirteen patients three years after their MACI surgery. According to their study using MACI is effective for chondral defects that are larger, as they studied patients with defect area of 8.1 cm<sup>2</sup> on average. They report a functional ICRS score increase from 0% to 91.7% at three years post-operation. Their other conclusion was similar to the first study as they mentioned that more long-term data on patients who underwent MACI should be gathered, they also suggested that their sample size of thirteen isn't a large number that you can base recommendations for the general population on (33).

At this point clinical trials of MACI were done only on a small sample size of patients, it is important to get a broader sample size of population with a variety of ages and chondral injuries to get a better clinical pictures of the outcomes of MACI. An example for that is a study also originating from Germany on a bigger and more diverse sample size of fifty patients. The study consisted of patients aged 14-44 with varying locations of chondral injuries in the knee, medial or lateral condyle, patella and trochlea. The defect size also varied from 1.6-6.1 cm<sup>2</sup>. These patients were followed-up at an average of two years post-operation. The results showed significant improvements in all scores and measures with 54% of patients reporting their results as an excellent outcome, while 28% reported great results (34).

Another MACI study tried to evaluate objectively the repair process after MACI surgery using osteochondral marker proteins as a quantitative tool. The researchers used CaReS as their implanted biodegradable matrix in which the autologous chondrocytes were embedded before the implantation, as with similar studies. The study used nineteen patients who underwent MACI procedure and evaluated them at 6, 12, 26 and 52 weeks following the surgery. On each follow-up a synovial fluid sample was produced and various osteochondral markers were examined each time. The osteochondral markers were compared to clinical scores and an MARI that was done for the patients.

The study concluded that after 52 weeks since having the surgery the osteochondral markers changed significantly. Almost all the markers except one that were measured dropped in concentration after week 6 post-surgery. With all markers returning to pre-operative concentrations after week 26. On the other hand, significant statistical correlations between the markers concentrations and clinical scores were observed in only a few points during the post-operative phase. Due to the lack of correlation the researchers concluded that synovial fluid osteochondral marker proteins cannot be used objectively to determine cartilage changes and regeneration after MACI surgery for the period of 52 weeks (35).

## **7 ANALYSIS OF LITERATURE**

---

### **7.1 COMPARISON BETWEEN THREE GENERATIONS OF ACI**

Plenty of research was done during the development of the three generations of ACI. Most of the research showed promise and significant improvement in both clinical scores, imaging and histological appearance of most patients. So the question that rises is, which generation of ACI has the best results. Or we could also ask which generation of ACI is recommended to the general population considering different outcomes and potential adverse effects. Luckily, a few different comparative studies and random control trials did exactly that.

#### **7.1.1 First Generation Versus Second Generation**

Several studies have been conducted to compare the different ACI generations. In a study out of the United Kingdom a research group compared the first generation of ACI with the second generation of ACI. The first generation using the periosteal cover and the second generation using the type I/III collagen membrane. This was the first study of its kind that compared two different generations of ACI. So therefore, it was crucial to the authors to try and establish which generation is better in terms of outcome.

The study enlisted 68 patients (33 first generation ACI and 35 second generation ACI). All patients were followed-up two years post-operation. The mean age of the patients was 30 years old and the mean defect size of the injury was 4.54 cm<sup>2</sup>. They group had interesting results, after a clinical and functional assessment of each patient they found that more patients who had the second generation ACI with the collagen membrane had better results, 2 years post-surgery. The reported statistics were 74% of second generation ACI patients had excellent or good results compared to 67% of excellent or good outcome patients who had the first generation ACI. One might think that a 10% increase isn't that great of an achievement for choosing which technique is better but the research also reported that an arthroscopy done at time of one-year post-operation revealed that 36.4% of patients who had first generation ACI had graft hypertrophy, and required shaving of the graft, compared to 0% of reported hypertrophied grafts in the second generation ACI patient pool. This is a significant statistical difference between the two surgical techniques which strongly favors the second generation over the first. Therefore, the group suggests that the use of first generation periosteal covered ACI has no advantages over second generation collagen membrane covered ACI, and due to these results they will advocate the use of second generation ACI compared to the first generation (36).

### **7.1.2 First Generation Versus Third Generation**

Two studies that compared the first generation of ACI and the third generation of ACI (MACI). Both studies used similar patients pools and used similar ways to assess the outcomes of the surgeries in the form of clinical scores, imaging, arthroscopies and histological appearance. The two studies also followed-up on the patients two years post-operation. Both studies found a similar result which was a bit unexpected. They found that there was no statistical difference between the results of first and third generation ACI in the short and mid-term follow-ups. MRI that was performed of the patients one-year post-operation showed cartilage formation, and good integration of the cartilage in both patient pools (37). The other study concluded that even though the results are statistically comparable and there is no clear significance in the collected data to either techniques, they would recommend the long-term study of MACI even though it is more technically attractive to perform (38).

Another study comparing the first generation and the third found similar results, with one significant remark favoring the first generation ACI. The study was conducted on 21 patients, which clinical assessment that was done in a very similar manner to the other studies presented in this section. The group found that in the one-year and two-year post-operation points there were no significant differences except a significant increase in the Lysholm and Gillquist scores after one-year post ACI favoring the first generation ACI compared to the third generation. They concluded that this is the only significant differences between the procedures which favors the first generation periosteal covered ACI (39).

These comparative studies tried to solve the question of which generation of ACI is better. However, the results of these studies do not help with that question as there is no clear statistical favorite. Although, it is important to mention that none of these studies had long-term data post the two-year post-surgery mark. With the minor differences between the generations which point to the second generation being the better technique it is still not enough data to conclude that as a fact. It is also important to point out that there was no comparative study that was performed between the second and third generation ACI so therefore, the conclusion cannot be achieved as to which technique is better.



## **7.2 COMPARING ACI TO DIFFERENT CURRENT SURGICAL TECHNIQUES**

The comparison between the different generations of ACI is inconclusive without long-term studies, but with a different perspective we can use either one of the three generations when comparing them to other surgical techniques. This is of course a bit limiting but since the similarities between the different generations are plenty it would be acceptable. In this chapter ACI is compared against three major surgical techniques that are still being used as the standard treatment for chondral injuries. The techniques are: mosaicplasty, OCA and microfractures. All of which were explained in a previous chapter.

### **7.2.1 ACI and Mosaicplasty**

The first surgical technique being tested for efficacy against ACI is mosaicplasty. A study with the same goal has been conducted to answer this question. The study was composed of a total of a hundred patients with focal chondral injuries were randomly selected to undergo either mosaicplasty or ACI procedures. The mean age of these patients was 31.3 years old, most of the injuries were post-traumatic and had a mean defect area of 4.66 cm<sup>2</sup>. The follow-up of these patients was done between 12 to 26 months post-surgery. At the follow-ups a clinical assessment score was taken from the patients and the results were 88% of ACI patients had excellent or good results while only 69% had excellent or good results with mosaicplasty. Furthermore, a one-year arthroscopy showed 82% of patients had excellent or great repair compared to only 34% of patients who had mosaicplasty. They also mentioned that the five cases of patellar mosaicplasty have failed.

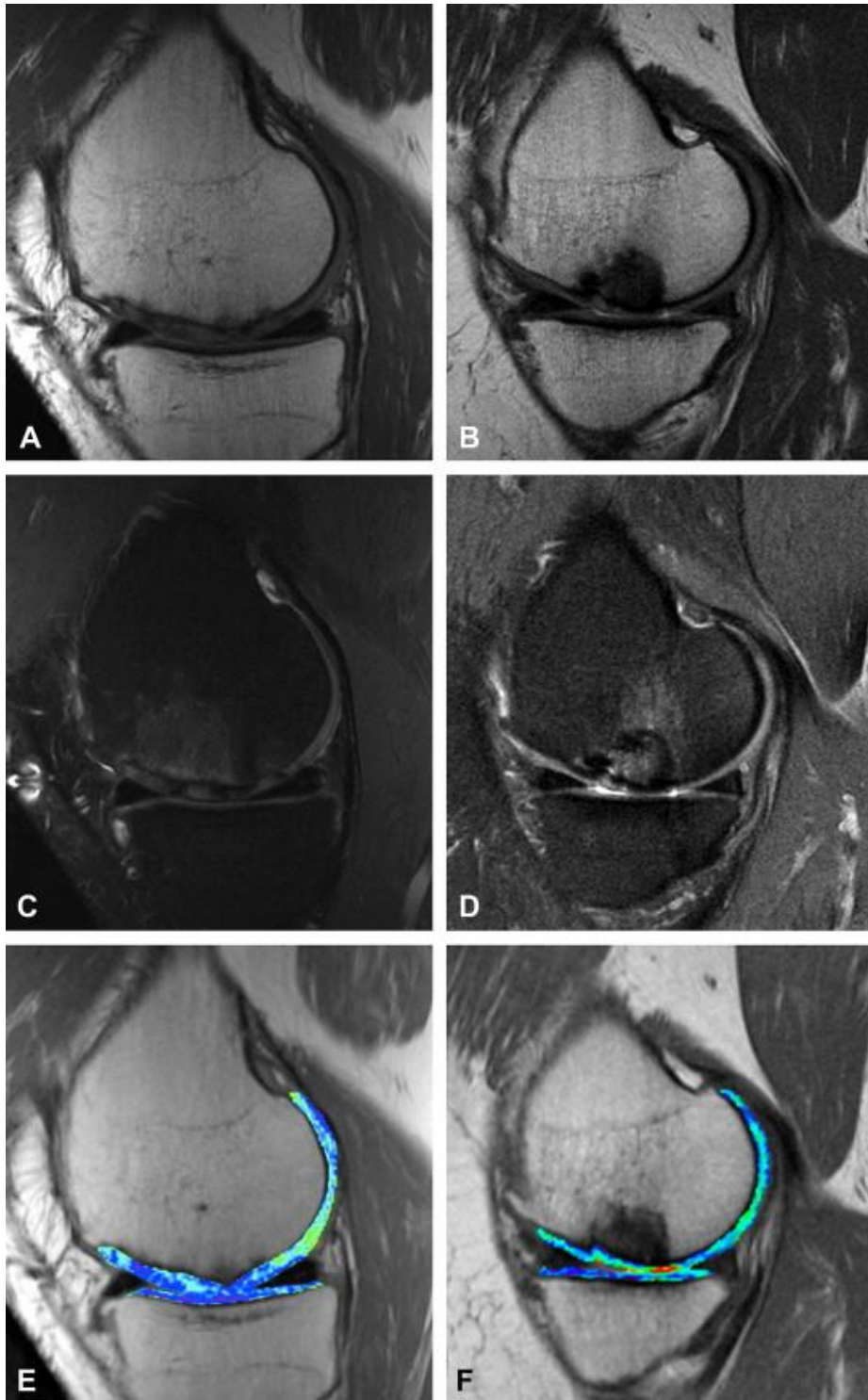
The group reported that their randomized control trial showed the superiority of ACI compared to mosaicplasty after 19 months average follow-up. The group notes, that their results for ACI are comparable to other isolated studies while compared to mosaicplasty it should raise questions about the use of this technique in the future (40). These results are in favor of ACI which shows superior results compared to mosaicplasty, but again, this study has not collected long-term data to compare the two.

### **7.2.2 ACI and OCA**

Another research group out of Germany decided to compare ACI and OCA using imaging methods. Their goal is to compare the repair cartilage tissue using T2 mapping assessments. T2 is a MRI technique that is commonly used to study the myocardium. The study compared eighteen patients of which nine underwent OCA and the other nine underwent MACI. They patients were matched for gender, age, Body Mass Index (BMI), injury location and post-surgical intervals. During they follow-ups the team preformed the T2 MRI as well as the different clinical assessment scores.

First the group reported that the T2 values of the femoral cartilage of the two different patient groups was statistically similar. They go on to report that the T2 value for ACI patients was 46.8 ms which was significantly lower compared to the T2 value of the OCT group which was 55.5 ms. Another interesting fact is that in the ACI group the T2 cartilage value was lower than the healthy femoral cartilage which was 52.5 ms. On the other hand, the clinical scores following ACI were superior to OCT, with only the Lysholm score reaching a significant comparable level (OCT 66.8 ACI 77.0). These results show the difference between structural outcome of the repair cartilage and the clinical score where ACI continues to show superiority. The results from the study are inconclusive and the group cannot suggest one technique over the other since

comparing which results, T2 MRI finding or clinical scores, can help them prove which technique is better (41).



*Figure 2.* MRI T1 (A,B), MRI T2 (C,D,E,F), ACI patients (A,C,E), OCT patients (B,D,F) (Salzmann et al. 2009)

### **7.2.3 ACI and Microfractures**

Microfractures is next to be compared to ACI. A study that was conducted to compare the two techniques was completed. Similar to the previous study, this study compared the two techniques using MRI to see which surgical procedure gives the best appearance of the repair cartilage tissue. The study was done on 112 patients with 86 of which had undergone microfractures and 35 had undergone ACI. The follow-up of the study was done after 15 months for the microfractures group of patients and 13 months for the ACI group. The group reports that the ACI group had better defect filling compared to microfractures they also reported that the repair cartilage tissue of the microfractures group was depressed compared to the surrounding native cartilage (42). This study shows that using imaging methods like MRI which can detect the quality of the repair cartilage, point us to ACI being a better treatment choice than microfractures for the time of 14 months average follow-up time post-surgery.

A long-term study comparing ACI and microfractures again shows a different set of results. The study conducted follow-up of patients as long as five years post-operation. There were eighty patients in total with 40 of which had ACI surgery and the other forty had microfractures surgery. The group collected data using clinical assessments scores as well as radiological findings. This type of long-term follow-up has not been done before in a way that compares ACI to a different surgical technique. The information from this study, if successful for ACI is vital to the standardization of it as a treatment option of chondral injuries.

The group reports the data after two years and after five years post-surgery. After five years post-surgery there were nine surgical failures in each group. The group mentions that they did not find correlating data between histological appearance of the cartilage and the clinical outcomes of the patients, but none of the patients who at the time of two years post-operation with a predominantly hyaline cartilage like histology had surgical failure at the time of the last follow-up done at five years post-operation. The study concludes that there were no statistical differences between the two groups after five years and that 77% of patients in both groups reported satisfactory outcome of the surgery (43). These results are also inconclusive with no clear understanding of which technique is better for the long-term health of the patients.

While comparing ACI to other surgical techniques it is evident that long-term outcomes and overall life improvement is the missing factor in determining if ACI is better than the rest. When looking at the short to mid-term data that most studies provide it is sometimes evident that ACI is better while in some cases (when compared with OCT) the data is inconclusive with conflicting findings. Another factor that needs to be studied is that can ACI lower the risk of osteoarthritis, and how is this risk lowered compared to the other surgical options. Since osteoarthritis is a disease that develops after a long time it is important to wait to collect enough long-term data on this subject. It is an important aspect of chondral surgeries that cannot be forgotten.

### **7.3 LONG-TERM STUDIES OF ACI**

The most important aspect of how successful ACI is has been emerging as the fact that will ACI show the same excellent results as it showed in the short and mid-term post-operation in the long-term post-operation. This question is integral to answer if we want to know how effective ACI is in treating chondral cartilage injuries of the knee joint. This section focuses on long-term studies that have shown exactly how effective ACI is in the period of time starting at five years post-surgery and going further to even after ten years post-surgery.

The first study to be discussed is a ten-year minimum follow-up by a research group from Boston. The group had three main objectives in this study; to understand the survivorship of ACI, long-term function assessed by using the agreeable clinical scoring tools, and finally to predict the potential factors for failure of the surgery. These questions could only be answered by a long-term study design like this one. The study included two hundred and ten patients who were treated with ACI that were followed for a mean period of 12 years. The mean age during the surgery was 36 and the mean area of the defect was 8.4 cm<sup>2</sup>.

It was reported that 53 out of 210 (25%) patients had suffered a failure of the surgery, and while 46 of them had a revision surgery the rest declined further treatment and two lost contact with the study. The rest of the patients scored an increase in all clinical scoring methods. They also report that the survivorship was higher in patients who had complex type of ACI compared to patients who had a salvage-type lesion. Survivorship was also higher in primary ACI compared to ACI after bone marrow stimulation, and higher in patients who didn't have a high tibial osteotomy versus those who underwent that procedure. This factors affect survivorship of ACI meaning that having any of those factors increases the risk of failure, and should be considered as a risk factor for the procedure. This study concludes that ACI had durable outcomes with 71% survivorship and 75% improved function after 10 years (44).

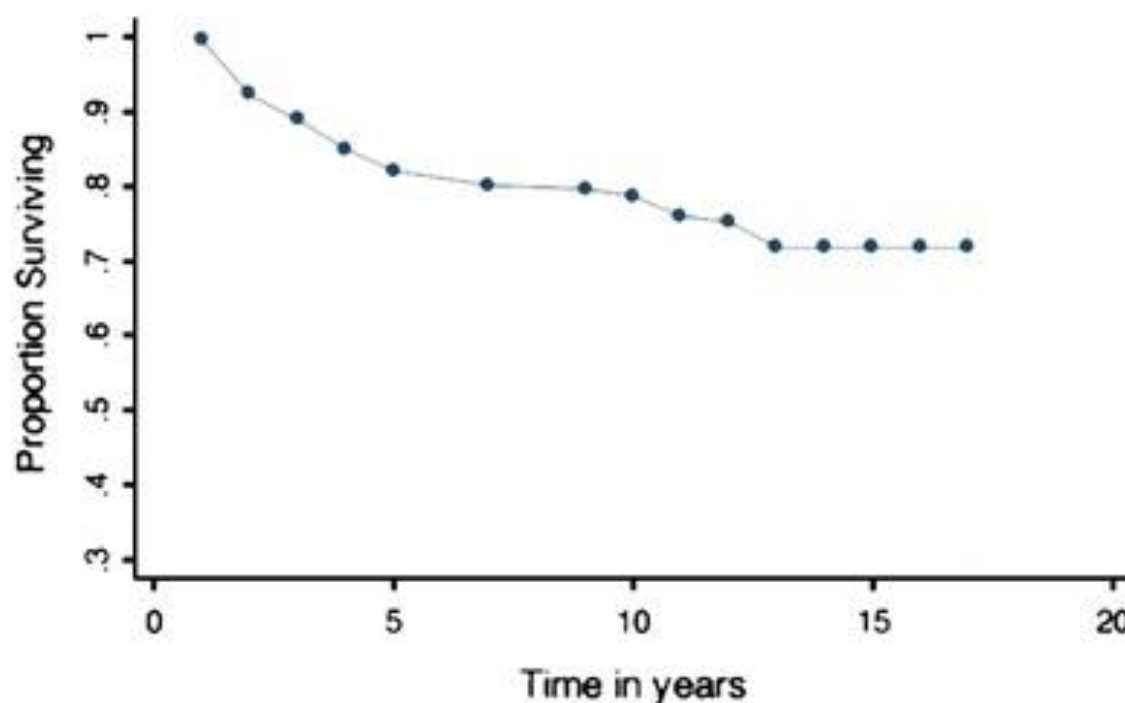


Figure 3. Survivorship of ACI after 5, 10 and 15 years post-surgery (Minas et al. 2014).

Another study of long-term results of ACI takes us to look at the ankle joint rather than the knee joint, but the results of this study show a comparable outcome to the studies of ACI done on knee joints. The study followed 10 patients who underwent ACI to repair osteochondral lesion of the talus. Their long-term efficacy was measured 10 years after the surgery and will be done using clinical scoring methods similar but not the same as those used to score the knee joint, and T2 MRI imaging studies.

The study reports a mean increase from 37.9 to 92.7 in the American Orthopedic Foot and Ankle Score. The T2 MRI findings reported that there was a well-modeled restoration of articular surface of the talus and the mean T2 score was 46 ms which is similar with that of a healthy cartilage. The study concludes that the results are in fact comparable to those of ACI done on the knee joint in the long-term follow-up. This was demonstrated by the formation of hyaline-cartilage, significant clinical improvement and the durability of the results (45). The group continues to add that T2 MRI studies have proved as a great evaluator method for the evaluation of cartilage in the ankle joint as it is good for the knee joint.

The next study to focus on is a systematic review done using data from 917 patients that were a part of thirteen different studies. The review focuses on whether there are patient-specific or defect-specific factors that should influence the use of ACI compared to other surgical procedures. The study goes on to show and improvement in all patients using different surgical techniques and point out some patient-specific factors that will help in considering ACI over a different procedure. One fact that was reported is that younger patients with shorter preoperative duration of symptoms and fewer prior surgical procedures had the best outcome with ACI and with microfractures. The group also found was that the size of a defect greater than 4 cm<sup>2</sup> was the only predictive defect-specific factor for a better outcome with ACI compared to non-autologous chondrocyte implantation surgical techniques (46).

The last long-term study this this section will focus on come from the group that first described the procedure of ACI out of the University of Gothenburg, Sweden, in this uncontrolled study the Peterson-Brittburg group evaluated 341 patients based on their clinical scores during a period of ten years post-surgery. They patients were also asked to grade their status during the past ten years as either better, worse or unchanged. They were also asked if they would repeat ACI if they had a choice.

The mean cartilage defect in these patients was 5.3 cm<sup>2</sup>. These patients reported after a mean period of 12.8 years post-surgery. 74% of these patients reported that they were better or the same during the post-surgical period. 92% of patients reported that they would have the procedure again if they had the choice. Otherwise, the group reports an increase in all clinical scores as compared to the pre-operative scores. The study concludes with the statement that ACI has been and effective and durable method for the treatment of large full-thickness cartilage and osteochondral lesion of the knee joint. It also states that even after an extended post-operation period of time 10-20 years the results with regard to function and clinical outcome remain high (47).

## 8 CONCLUSION

---

After a long literature review on the different procedures of cartilage and osteochondral repair of the knee joint it is evident that ACI emerges as one of the superior options for patients. Throughout the history of its development ACI has shown significant improvement in most if not all clinical scores, imaging and functional outcome in short, mid and long-term periods post-surgery. The innovative technology that allowed scientists and researchers to develop ACI is just the beginning in cell and regenerative therapy to use the body's own cells as a repair tool. As this technology improves over time it ACI might become the gold standard treatment for large chondral and osteochondral lesion of the knee joint (48) and as well as other joint, for example the ankle joint.

For most patients ACI has been a good treatment as many reported that they had an improvement in function and in fact many also reported that they will choose to undergo ACI again if they had the option of choosing. There is still limited information and unanswered questions regarding ACI such as the long-term risk reduction in developing osteoarthritis. Since osteoarthritis is a chronic condition that takes sometimes years to develop this question might be answered in the coming future. As time goes more surgical techniques for cartilage repair will emerge but it seems like the influence of ACI on these procedures will remain as it is becoming more common to use the body's own resources will be optimized ex-vivo to be introduced back to the body as the best alternative to classic repair. In conclusion, factor such as lesion size, physical fitness, and patient's age should be the main factors to consider when choosing a treatment option for them, as care is transitioning from surgeon-preferred choice to evidence based, optimal for the patient option the prevalence of ACI will be greater.

## 9 ACKNOWLEDGMENTS

---

I would personally like to thank my mentor Prof. dr. sc. Mislav Jelić for allowing me to pursue my interest in orthopedics and for providing this topic for my thesis. Since my fifth year of medical studies after I attended Prof. Jelić's lecture during Orthopedics course in the beginning of the year, I was especially inspired to choose him as my mentor for this thesis and for my clinical rotations. I hope you continue to inspire more medical students in the future. I would also like to thank Prof. dr. sc. Domagoj Delimar and his Orthopedics department for their help during my clinical rotations in the department. I would also like to thank my family for their emotional and financial support during my studies and their help in guiding me to find what I am most interested in, and to follow that through. Lastly I would like to thank my partner for the last two years Maja who helped in pushing me and reinforcing me with motivation to keep going, she also helped in translating the chapter SAŽETAK in this thesis to Croatian.

## 10 REFERENCES

---

1. Brukner, P. (2017). *Brukner and Khan's Clinical Sports Medicine: Injuries* (5th ed., Vol. 1). McGraw-Hill Education (Australia) Pty Ltd.
2. Steinwachs, M. R. (2011). Scientific Evidence Base for Cartilage Injury and Repair in the Athlete. *Sage Journals Home*, 3(1). <https://doi.org/10.1177/1947603511415841>
3. Flanigan, D. C. (2010). Prevalence of Chondral Defects in Athletes' Knees A Systematic Review. *Medicine & Science in Sports & Exercise*, 42(10). <https://doi.org/10.1249/MSS.0b013e3181d9eea0>
4. Cole, B., Seroyer, S., Filardo, G., Bajaj, S., & Fortier, L. (2010). Platelet-rich plasma: Where are we now and where are we going? *Sports Health*, 2(3). <https://doi.org/10.1177/1941738110366385>
5. Azar, F., Canale, S. T., & Beaty, J. H. (2021). *Campbell's Operative Orthopaedics* (14th ed., Vol. 1). Elsevier.
6. Goyal, D., Keyhani, S., Lee, E. H., & Hoi Po Hui, J. (2013). Evidence-based status of microfracture technique: A systematic review of level I and II studies. *Arthroscopy Association of North America. Published by Elsevier Inc.*, 29(9). <https://doi.org/10.1016/j.arthro.2013.05.027>
7. Harris, J. D., Brophy, R. H., Siston, R. A., & Flanigan, D. C. (2010). Treatment of chondral defects in the athlete's knee. *Arthroscopy Association of North America. Published by Elsevier Inc.*, 26(6). <https://doi.org/10.1016/j.arthro.2009.12.030>
8. Kent, A. (2010, July 26). Microfracture knee surgery and its impact on the NBA. *The Good Point*. 2012-07-23.
9. Gudas, R., Kalesinskas, R., Kimtys, V., Stankevicius, E., Toliushis, V., Bernotavicius, G., & Smailys, A. (2005). A prospective randomized clinical study of mosaic osteochondral autologous transplantation versus microfracture for the treatment of osteochondral defects in the knee joint in young athletes. *Arthroscopy Association of North America. Published by Elsevier Inc.*, 21(9). <https://doi.org/10.1016/j.arthro.2005.06.018>
10. Gudas, R., Simonaityte, R., Cekanauskas, E., & Tamosiūnas, R. (2009). A prospective, randomized clinical study of osteochondral autologous transplantation versus microfracture for the treatment of osteochondritis dissecans in the knee joint in children. *Journal of Pediatric Orthopaedics*, 29(7). <https://doi.org/10.1097/BPO.0b013e3181b8f6c7>
11. Krych, A. J., Harnly, H. W., Rodeo, S. A., & Williams, R. J. I. (2012). Activity levels are higher after osteochondral autograft transfer mosaicplasty than after microfracture for



- articular cartilage defects of the knee: A retrospective comparative study. *The Journal of Bone & Joint Surgery*, 94(11). <https://doi.org/10.2106/JBJS.K.00815>
12. Hangody, L., & Füles, P. (2003). Autologous Osteochondral Mosaicplasty for the Treatment of Full-Thickness Defects of Weight-Bearing Joints Ten Years of Experimental and Clinical Experience. *He Journal of Bone & Joint Surgery*, 85(2). <https://doi.org/10.2106/00004623-200300002-00004>
  13. Abe, K., & Tsumaki, N. (2023). Regeneration of joint surface defects by transplantation of allogeneic cartilage: Application of iPS cell-derived cartilage and immunogenicity. *Inflammation and Regeneration*, 43(56). <https://doi.org/10.1186/s41232-023-00307-0>
  14. Adkisson, H., Milliman, C., Zhang, X., Mauch, K., Maziarz, R., & Streeter, P. (2010). Immune evasion by neocartilage-derived chondrocytes: Implications for biologic repair of joint articular cartilage. *Stem Cell Research*, 4(1). <https://doi.org/10.1016/j.scr.2009.09.004>
  15. Bentley, G., & Greer, R. B. I. (1971). Homotransplantation of Isolated Epiphyseal and Articular Cartilage Chondrocytes into Joint Surfaces of Rabbits. *Nature*, 230. <https://doi.org/10.1038/230385a0>
  16. Kawabe, N., & Yoshinao, M. (1991). The repair of full-thickness articular cartilage defects. Immune responses to reparative tissue formed by allogeneic growth plate chondrocyte implants. *Clinical Orthopaedics and Related Research*, 268. <https://europepmc.org/article/med/2060220>
  17. Hyc, A., Malejczyk, J., Osiecka, A., & Moskalewski, S. (1997). Immunological Response against Allogeneic Chondrocytes Transplanted into Joint Surface Defects in Rats. *Cell Transplantation*, 6(2). <https://doi.org/10.1177/096368979700600205>
  18. Monaco, G., El Haj, A. J., Alini, M., & Stoddart, M. J. (2021). Ex Vivo Systems to Study Chondrogenic Differentiation and Cartilage Integration. *Journal of Functional Morphology and Kinesiology*, 6(6). <https://doi.org/10.3390/jfmk6010006>
  19. Bexkens, R., Ogink, P., Doornberg, J., Kerkhoffs, G., Eygendaal, D., Oh, L., & van den Bekerom, M. (2017). Donor-site morbidity after osteochondral autologous transplantation for osteochondritis dissecans of the capitellum. *Knee Surgery, Sports Traumatology, Arthroscopy*, 25(7). <https://doi.org/10.1007/s00167-017-4516-8>
  20. McCarthy, H., Richardson, J., Parker, J., & Roberts, S. (n.d.). Evaluating Joint Morbidity after Chondral Harvest for Autologous Chondrocyte Implantation (ACI). *Cartilage*, 7(1). <https://doi.org/10.1177/1947603515607963>

21. Niemeyer, P., Schubert, T., Grebe, M., & Hoburg, A. (2019). Treatment Costs of Matrix-Associated Autologous Chondrocyte Implantation Compared With Microfracture. *Orthopaedic Journal of Sports Medicine*, 7(12). <https://doi.org/10.1177/2325967119886583>
22. Moradi, B., Schönit, E., Nierhoff, C., Hagmann, S., Oberle, D., Gotterbarm, T., Schmitt, H., & Zeifang, F. (2012). First-generation autologous chondrocyte implantation in patients with cartilage defects of the knee: 7 to 14 years' clinical and magnetic resonance imaging follow-up evaluation. *Arthroscopy Association of North America. Published by Elsevier Inc.*, 28(12). <https://doi.org/10.1016/j.arthro.2012.05.883>
23. Hurley, E., Davey, M., Jamal, M., Manjunath, A., Alaia, M., & Strauss, E. (2019). Return-to-Play and Rehabilitation Protocols following Cartilage Restoration Procedures of the Knee: A Systematic Review. *Cartilage*, 13(1). <https://doi.org/10.1177/1947603519894733>
24. Triana, J., Li, Z., Rao, N., Kingery, M., & Strauss, E. (2023). Return to Play After Knee Articular Cartilage Restoration: Surgical Options, Rehabilitation Protocols, and Performance Outcomes. *Current Reviews in Musculoskeletal Medicine*, 16(12). <https://doi.org/10.1007/s12178-023-09872-w>
25. Roberts, S., Menage, J., Sandell, L., Evans, E., & Richardson, J. (2009). Immunohistochemical study of collagen types I and II and procollagen IIA in human cartilage repair tissue following autologous chondrocyte implantation. *Knee*, 16(5). <https://doi.org/10.1016/j.knee.2009.02.004>
26. Franceschi, F., Longo, U., Ruzzini, L., Marinozzi, A., Maffulli, N., & Denaro, V. (2008). Simultaneous arthroscopic implantation of autologous chondrocytes and high tibial osteotomy for tibial chondral defects in the varus knee. *Knee*, 15(4). <https://doi.org/10.1016/j.knee.2008.04.007>
27. Rosenberger, R., Gomoll, A., Bryant, T., & Minas, T. (2008). Repair of large chondral defects of the knee with autologous chondrocyte implantation in patients 45 years or older. *The American Journal of Sports Medicine*, 36(12). <https://doi.org/10.1177/0363546508322888>
28. Marcacci, M., Kon, E., Zaffagnini, S., Filardo, G., Delcogliano, M., Neri, M., Iacono, F., & Hollander, A. (2007). Arthroscopic second generation autologous chondrocyte implantation. *Knee Surgery, Sports Traumatology, Arthroscopy*, 15(5). <https://doi.org/10.1007/s00167-006-0265-9>
29. Ossendorf, C., Kaps, C., Kreuz, P., Burmester, G., Sittlinger, M., & Erggelet, C. (2007). Treatment of posttraumatic and focal osteoarthritic cartilage defects of the knee with

- autologous polymer-based three-dimensional chondrocyte grafts: 2-year clinical results. *Arthritis Research & Therapy*, 9(2). <https://doi.org/10.1186/ar2180>
30. Nehrer, S., Chiari, C., Domayer, S., Barkay, H., & Yaron, A. (2008). Results of chondrocyte implantation with a fibrin-hyaluronan matrix: A preliminary study. *Clinical Orthopaedics and Related Research*, 466(8). <https://doi.org/10.1007/s11999-008-0322-4>
  31. Marlovits, S., Zeller, P., Singer, P., Resinger, C., & Vécsei, V. (2005). Cartilage repair: Generations of autologous chondrocyte transplantation. *European Journal of Radiology*, 57(1). <https://doi.org/10.1016/j.ejrad.2005.08.009>
  32. Andereya, S., Maus, U., Gavenis, K., Gravius, S., Stanzel, S., Müller-Rath, R., Miltner, O., Mumme, T., & Schneider, U. (2007). Treatment of patellofemoral cartilage defects utilizing a 3D collagen gel: Two-year clinical results. *Zeitschrift für Orthopädie und Unfallchirurgie*, 145(2). <https://doi.org/10.1055/s-2007-965181>
  33. Maus, U., Schneider, U., Gravius, S., Müller-Rat, R., Mumme, T., Miltner, O., Bauer, D., Niedhart, C., & Andereya, S. (2008). Clinical results after three years use of matrix-associated ACT for the treatment of osteochondral defects of the knee. *Zeitschrift für Orthopädie und Unfallchirurgie*, 146(1). <https://doi.org/10.1055/s-2007-989353>
  34. Anders, S., Schaumburger, J., Schubert, T., Grifka, J., & Behrens, P. (2008). Matrix-associated autologous chondrocyte transplantation (MACT). Minimally invasive technique in the knee. *Operative Orthopädie und Traumatologie*, 20(3). <https://doi.org/10.1007/s00064-008-1303-1>
  35. Gravius, S., Schneider, U., Mumme, T., Bauer, D., Maus, U., Müller-Rath, R., Berdel, P., Siebert, C., & Andereya, S. (2007). Osteochondral marker proteins in the quantitative evaluation of matrix-based autologous chondrocyte transplantation CaRes. *Zeitschrift für Orthopädie und Unfallchirurgie*, 145(5). <https://doi.org/10.1055/s-2007-965724>
  36. Gooding, C., Bartlett, W., Bentley, G., Skinner, J., Carrington, R., & Flanagan, A. (2006). A prospective, randomised study comparing two techniques of autologous chondrocyte implantation for osteochondral defects in the knee: Periosteum covered versus type I/III collagen covered. *Knee*, 13(3). <https://doi.org/10.1016/j.knee.2006.02.011>
  37. Manfredini, M., Zerbinati, F., Gildone, A., & Faccini, R. (2007). Autologous chondrocyte implantation: A comparison between an open periosteal-covered and an arthroscopic matrix-guided technique. *Acta Orthopaedica Belgica*, 73(2). <https://pubmed.ncbi.nlm.nih.gov/17515233/>
  38. Bartlett, W., Skinner, J., Gooding, C., Carrington, R., Flanagan, A., Briggs, T., & Bentley, G. (2005). Autologous chondrocyte implantation versus matrix-induced autologous chondrocyte

- implantation for osteochondral defects of the knee: A prospective, randomised study. *The Journal of Bone and Joint Surgery*, 87(5). <https://doi.org/10.1302/0301-620X.87B5.15905>
39. Zeifang, F., Oberle, D., Nierhoff, C., Richter, W., Moradi, B., & Schmitt, H. (2010). Autologous chondrocyte implantation using the original periosteum-cover technique versus matrix-associated autologous chondrocyte implantation: A randomized clinical trial. *The American Journal of Sports Medicine*, 38(5). <https://doi.org/10.1177/0363546509351499>
40. Bentley, G., Biant, L., Carrington, R., Akmal, M., Goldberg, A., Williams, A., Skinner, J., & Pringle, J. (2003). A prospective, randomised comparison of autologous chondrocyte implantation versus mosaicplasty for osteochondral defects in the knee. *The Journal of Bone & Joint Surgery*, 85(2). <https://doi.org/10.1302/0301-620x.85b2.13543>
41. Salzman, G., Paul, J., Bauer, J., Woertler, K., Sauerschnig, M., Landwehr, S., Imhoff, A., & Schöttle, P. (2009). T2 assessment and clinical outcome following autologous matrix-assisted chondrocyte and osteochondral autograft transplantation. *Osteoarthritis Cartilage*, 17(12). <https://doi.org/10.1016/j.joca.2009.07.010>
42. Brown, W., Potter, H., Marx, R., Wickiewicz, T., & Warren, R. (2004). Magnetic resonance imaging appearance of cartilage repair in the knee. *Clinical Orthopaedics and Related Research*, 422. <https://doi.org/10.1097/01.blo.0000129162.36302.4f>
43. Knutsen, G., Drogset, J., Engebretsen, L., Grøntvedt, T., Isaksen, V., Ludvigsen, T., Roberts, S., Solheim, E., Strand, T., & Johansen, A. (2007). A randomized trial comparing autologous chondrocyte implantation with microfracture. Findings at five years. *The Journal of Bone & Joint Surgery*, 89(10). <https://doi.org/10.2106/JBJS.G.00003>
44. Minas, T., Von Keudell, A., Bryant, T., & Gomoll, A. (2014). The John Insall Award: A minimum 10-year outcome study of autologous chondrocyte implantation. *Clinical Orthopaedics and Related Research*, 472(1). <https://doi.org/10.1007/s11999-013-3146-9>
45. Minas, T., Von Keudell, A., Bryant, T., & Gomoll, A. (2014). The John Insall Award: A minimum 10-year outcome study of autologous chondrocyte implantation. *Clinical Orthopaedics and Related Research*, 472(1). <https://doi.org/10.1007/s11999-013-3146-9>
46. Harris, J., Siston, R., Pan, X., & Flanigan, D. (2010). Autologous chondrocyte implantation: A systematic review. *The Journal of Bone & Joint Surgery*, 92(12). <https://doi.org/10.2106/JBJS.J.00049>
47. Peterson, L., Vasiliadis, H., Brittberg, M., & Lindahl, A. (2010). Autologous chondrocyte implantation: A long-term follow-up. *The American Journal of Sports Medicine*, 38(6). <https://doi.org/10.1177/0363546509357915>

48. Bekkers, J., Inklaar, M., & Saris, D. (2009). Treatment selection in articular cartilage lesions of the knee: A systematic review. *The American Journal of Sports Medicine*, 37(1).  
<https://doi.org/10.1177/0363546509351143>

## 11 BIOGRAPHY

---

Tal Menaged is a medical student in the final year of studies in the University of Zagreb, School of Medicine – Medical studies in English Program. He was born in 12<sup>th</sup> of February 1992, in Haifa, Israel. During his studies he was elected as the class representative for the fourth year, as well as representing his class in the school's EMED council for that year. He was a participant of CROSS – Croatian Student Summit during his studies in the year 2020 which focused on neurology and neuroscience. He is especially interested in orthopedics as well as sport medicine, and also has appreciation to learning about new medical and surgical findings.

In high school he majored in biology and music. After graduating high school Tal enlisted to the IDF – Israeli Defense Force serving as a navigation and control operator as well as defensive coordinator in the Navy's missile cruiser battle ships for three years. Before enrolling in the school of medicine Tal was working as a quality insurance testing group leader for three years. During that work he was exposed to the technological world and to work as a leader.

In his free time Tal enjoys playing various musical instruments, cooking, recreational sports and the outdoors.