

Right ventricular loading conditions in left ventricular assist device recipients

Gaberšek, Ana

Master's thesis / Diplomski rad

2016

Degree Grantor / Ustanova koja je dodijelila akademski / stručni stupanj: **University of Zagreb, School of Medicine / Sveučilište u Zagrebu, Medicinski fakultet**

Permanent link / Trajna poveznica: <https://um.nsk.hr/um:nbn:hr:105:700349>

Rights / Prava: [In copyright](#) / [Zaštićeno autorskim pravom.](#)

Download date / Datum preuzimanja: **2024-09-16**



Repository / Repozitorij:

[Dr Med - University of Zagreb School of Medicine Digital Repository](#)



**UNIVERSITY OF ZAGREB
SCHOOL OF MEDICINE**

Ana Gaberšek

**Right ventricular loading conditions in
left ventricular assist device
recipients**

GRADUATE THESIS



Zagreb, 2016

This graduation paper was made at the Department of cardiovascular diseases, at University Hospital Centre Zagreb, University of Zagreb, School of Medicine under supervision of Assistant professor Maja Čikeš, MD, PhD and it was submitted for evaluation in the academic year 2015/2016.

Mentor: Assistant professor Maja Čikeš, MD, PhD

LIST OF ABBREVIATIONS AND EXPLANATIONS

AVR	Aortic valve repair
BSA	Body surface area
CI	Cardiac index
CMP	Cardiomyopathy
CVP	Central venous pressure
dPAP	Diastolic pulmonary artery pressure
LV	Left ventricle
LVAD	Left ventricular assist device
LVNC	Left ventricular noncompaction
LVF	Left ventricular failure
MCS	Mechanical circulatory support
MI	Myocardial infarction
mPAP	Mean pulmonary artery pressure
NYHA	New York Heart Association
PAP	Pulmonary artery pressure
PCWP	Pulmonary capillary wedge pressure
pts	Patients
PVR	Peripheral vascular resistance
RA	Right atrium
RAP	Right atrial pressure
RAVol	Right atrial volume
RHC	Right heart catheterization
ROC AUC	Receiver-operating characteristics area under curve
RVSWI	Right ventricular stroke work index
RVA	Right ventricular asymmetry index
RVAD	Right ventricular assist device
RV	Right ventricle
RVF	Right ventricular failure
RVFAC	Right ventricular fractional area change
RVIDd	Right ventricular internal dimension in diastole

sPAP	Systolic pulmonary artery pressure
TAPSE	Tricuspid annular plane systolic excursion
TPG	Transpulmonary gradient
TR	Tricuspid regurgitation
VAD	Ventricular assist device

TABLE OF CONTENTS

1. SUMMARY	
2. PREFACE	1
2.1. HEART FAILURE.....	1
2.2. HEART FAILURE CLASSIFICATION	1
2.3. TREATMENT OPTIONS FOR PATIENS WITH HEART FAILURE	2
2.4. PATIENT SELECTION FOR VAD IMPLANTATION	2
2.5. COMPLICATIONS FOLLOWING LVAD IMPLANTATION.....	2
2.6. THE RIGHT VENTRICLE.....	3
2.7. POSTOPERATIVE RV FAILURE.....	3
2.8. ECHOCARDIOGRAPHY	4
2.8.1. ECHOCARDIOGRAPHIC IMAGES.....	5
2.8.2. ECHOCARDIOGRAPHIC WINDOWS	6
3. BACKGROUND	6
4. METHODS	7
5. RESULTS	9
6. DISCUSSION	14
7. CONCLUSION	16
8. ACKNOWLEDGEMENTS	17
9. REFERENCES	18
10. BIOGRAPHY	21

1. SUMMARY

Title: Right ventricular loading conditions in left ventricular assist device recipients

Author: Ana Gaberšek

Summary:

A ventricular assist device is a type of mechanical circulatory support used in patients with advanced heart failure. Left ventricular assist devices (LVAD) can be used as destination therapy, where they are an alternative to heart transplantation, bridge to transplant therapy or bridge to recovery therapy. The most common complication in the immediate postoperative period after LVAD implantation is right ventricular failure. It is challenging to determine which patients may develop right ventricular failure in the postoperative period, and there is no equivocal evidence in the literature suggesting which parameters might be optimal in predicting right ventricular failure (RVF).

The aim of this study was to identify and obtain clinical, hemodynamic and echocardiographic parameters that could successfully predict RVF in LVAD recipients. For this we have studied 40 consecutive patients at the University Hospital Centre Zagreb in which we have measured parameters of heart geometry and function by echocardiography, as well as functional and hemodynamic values by right heart catheterization which were used in combination with clinical parameters for the prediction of early and late RVF.

Key words: advanced heart failure, ventricular assist device, right heart failure, right ventricular function.

2. PREFACE

2.1. HEART FAILURE

Heart failure is a condition which occurs when heart function is too poor to pump a sufficient amount of blood to meet the needs of a body. Some causes of heart failure are: previous coronary artery disease with myocardial infarction, arterial hypertension, various cardiomyopathies, arrhythmias, congenital heart defects and dysfunction of heart valves. Signs and symptoms of heart failure include shortness of breath (dyspnea), lung edema, edema of extremities, intolerance of physical activity, fatigue, syncope, hepatosplenomegaly, inability to lie flat (orthopnea) and waking up during the night due to shortness of breath (paroxysmal nocturnal dyspnea).

2.2. HEART FAILURE CLASSIFICATION

According to the American Heart Association [1], there are four functional classes, to which we can assign patients according to their symptoms of heart failure. Patients without limitation of physical activity or patients whose ordinary physical activity does not cause undue fatigue, palpitation, dyspnea would be assigned to New York Heart Association (NYHA) Class I. Patients with slight limitation of physical activity, that are comfortable at rest or patients, in which ordinary physical activity results in fatigue, palpitations, dyspnea would be assigned to NYHA Class II. Patients with a marked limitation of physical activity, that are comfortable at rest, or patients in which less than ordinary activity causes fatigue, palpitation, or dyspnea would be assigned to NYHA Class III. Patients who are unable to carry on any physical activity without discomfort, patients that have symptoms of heart failure at rest and patients in which, if any physical activity is undertaken, discomfort increases are classified as NYHA Class IV.

In early stages of heart failure, symptoms can be managed with optimal medical therapy and lifestyle modification, however, this may become insufficient due to heart weakening as the condition progresses. According to the European Society of Cardiology 2016 Guidelines, one can describe heart failure as advanced heart failure when patients experience repeated cardiac decompensations, severe symptoms of heart failure or severe dysfunction of the heart [2].

2.3. TREATMENT OPTIONS FOR PATIENTS WITH HEART FAILURE

There are two main treatment options for advanced heart failure patients. One of the options is orthotopic heart transplantation – a surgical procedure by which a patient’s own failing heart is replaced through median sternotomy with a donor heart [3]. The alternative option is treatment with mechanical circulatory support (MCS) which encompasses surgical or percutaneous implantation of various devices – amongst others, ventricular assist devices. Left ventricular assist devices are mechanical pumps, that are implanted in order to aid the failing left ventricle in providing adequate circulation to the body [4].

Ventricular assist devices can be classified according to the nature of blood flow they produce into pulsatile devices, driving blood in pulsatile manner and continuous flow devices, producing axial blood flow [4,5].

2.4. PATIENT SELECTION FOR LVAD IMPLANTATION

Patient selection for left ventricular assist device (LVAD) implantation is cumbersome. There are numerous factors that need to be carefully studied when selecting patients. Detailed evaluation of echocardiographic parameters and values obtained by right ventricular catheterization has to be performed. Comorbidities such as age, chronic kidney disease and diabetes also need to be taken into consideration, since they can have a great impact on outcomes in LVAD recipients. There are multiple other factors also influencing patient outcomes after LVAD implantation, and it is not yet clear which are most relevant.

2.5. COMPLICATIONS FOLLOWING LVAD IMPLANTATION

Patients who received LVAD are at risk for developing driveline infection, thromboembolic events, postoperative bleeding and right ventricular failure (RVF) [5]. Infection of a transcutaneous driveline is common and it is associated with increased morbidity and mortality. A driveline infection can occur at the time of insertion or at any time in the postoperative period. Most driveline infections occur after the first 30 days after surgery [6].

Risk of developing thromboembolic events after LVAD implantation accounts for less than 20% of complications [3], regardless of the type of the device. Incidence of postoperative bleeding is still higher than 20%, and it remains one of the most common complications following LVAD placement, mostly requiring redo surgical procedures [7].

2.6. THE RIGHT VENTRICLE

The right ventricle is one of the four chambers of the heart and it extends from the right atrium to the apex of the heart, forming the majority of the anterior heart surface. It has an inlet section (sinus section) and an outlet (conus) section which are separated by the crista supraventricularis. The right ventricular wall has two layers of muscles. Superficial muscle layer fibers extend to the left ventricle, which allows coordinated contractions of both ventricles [8, 9].

Primary function of the right ventricle is the receipt of systemic venous return and pumping it into the pulmonary arteries. Blood enters the right ventricle from the right atrium, through the tricuspid valve, and flows from the right ventricle through the pulmonary valve into the pulmonary trunk, which carries blood further to the lungs for oxygenation. Right ventricular function depends on the preload, afterload and contractility of the ventricle. Stroke volume of the right ventricle is the same as the stroke volume of the left ventricle, except that the right ventricle pumps with approximately 15% of the stroke work, due to low resistance and pressures in pulmonary circulation [8]. The dimensions and systolic function of the right ventricle can primarily be assessed with echocardiography, using a combination of various echocardiographic parameters.

2.7. POSTOPERATIVE RV FAILURE

The most common complication in the immediate postoperative period after LVAD implantation is right ventricular failure [10,11]; therefore, it is important to properly evaluate all the parameters that might facilitate the preoperative and postoperative risk assessment. According to the Interagency Registry for Mechanically Assisted Circulatory Support (INTERMACS) [12], right ventricular failure is defined as

persistent signs and symptoms of RV dysfunction evident by central venous pressure (CVP) > 18 mmHg with cardiac index (CI) < 2.0 L /min/ m² in the absence of increased left atrial filling pressure/ pulmonary capillary wedge pressure (PCWP) >18 mmHg, cardiac tamponade, ventricular arrhythmias and/or pneumothorax, requiring either RVAD implantation, inhaled nitric oxide or inotropic therapy for 14 days or more after LVAD has been implanted.

INTERMACS [12] further classifies RVF according to severity in three classes:

- Severe, when RVAD is required
- Moderate, when there is a need for inotropes or inhaled pulmonary vasodilators
- Mild, when two or more of the following signs and symptoms are present: CVP >18 mmHg, CI < 2.3 L/min/m², ascites, moderate to severe peripheral edema, evidence of high CVP on physical examination or transthoracic echocardiogram, but without the need for RVAD or inotropic/vasodilator support.

Right ventricular failure after LVAD implantation occurs because of the alteration of Frank – Starling forces of the right ventricle as a result of unloading of the left ventricle, which leads to an increase of cardiac output and increase in preload of an already weakened and poorly contracting right ventricle, that has to pump against high afterload. Additionally, the worsening of tricuspid regurgitation (TR) and leftward bowing of the septum can occur, which further aggravates this condition [12].

2.8. ECHOCARDIOGRAPHY

Echocardiography is a non-invasive technique of visualisation of the heart, which can be used for diagnostic and therapeutic purposes. With echocardiography it is possible to obtain information about heart chamber geometry and myocardial structure and function, including the assessment of cardiac hemodynamic properties (by Doppler echocardiography). Echocardiography can also assess the morphology and function of the heart valves, aid in the detection of masses within the heart and assessment of the pericardium.

2.8.1. ECHOCARDIOGRAPHIC IMAGES

Ultrasound transducers use piezoelectric crystals, which have the ability to transform electrical oscillations into mechanical oscillations, to generate and receive ultrasound waves. The formation of the image is based on the time interval between the transmission of the ultrasound and return of the reflected signal back to the transducer (probe), which means that the image formation is related to the distance of a structure from the transducer. Several imaging modalities exist in echocardiography: two-dimensional (2-D) imaging, motion or so called "M"-mode imaging, Doppler imaging (continuous wave, pulsed wave and color flow), as well as advanced imaging techniques such as three-dimensional (3-D) imaging and deformation imaging (strain and strain-rate imaging).

A two-dimensional image is generated through complex manipulation of the returned signal (time-gain compensation, signal amplification, filtering, compression and rectification), to form a final image displayed on the echocardiography monitor. The 2-D mode captures a snapshot of the tissue cross-section and when those snapshots are produced quickly in a short amount of time, this allows the real-time imaging of the heart [8]. When the signal is produced and returned along one line, this denotes the motion mode. Motion mode (M-mode) has high sensitivity in detection of moving structures at high temporal resolution, which is of great importance in the identification of subtle heart abnormalities, such as for example valve leaflet abnormalities. Since it shows the motion of the heart, it also enables the operator to measure heart dimensions such as the size of heart chambers during the heart cycle or heart muscle thickening, also allowing for the precise timing of such events within the heart cycle.

The basic principle of Doppler echocardiography uses the detection of changes in frequency of the returned signal, that has been reflected from the red blood cells. Doppler echocardiography is mostly used to assess velocity information and to detect heart abnormalities such as shunts and valvular problems (stenoses, regurgitations, insufficiencies). Additionally color Doppler feature allows the operator to examine the flow of blood within the heart.

2.8.2. ECHOCARDIOGRAPHY WINDOWS

Different placements of the ultrasound transducer allow us to visualise different planes of the heart. Possible transducer placements include: suprasternal, right and left parasternal, subcostal and apical. The heart can be visualised in several standard imaging planes: the long-axis plane, the short-axis plane and the apical four-, five-, two- and three-chamber planes.

When placing the transducer at the left parasternal window, the operator is able to examine the long-axis view and short-axis views. The long-axis plane is the plane that slices the heart from its base to the apex of the heart. Many short-axis views can be obtained by changing of the angulation of the transducer, but usually the operator examines short-axis view at the level of the aortic valve, mitral valve, left ventricular papillary muscles and at the apex of the left ventricle [8]. The four-chamber view can be obtained through the apical window, with placement of the transducer to the apex of the heart.

Another view obtained through the apical window is the five-chamber view, which is of great importance in determining aortic valve abnormalities, because it allows visualisation of the aortic valve and ascending aorta. The two-chamber view can be obtained by rotating the probe on the apex of the heart, which enables examination of the left ventricle. The subcostal window is used particularly when examining the interatrial septum, abdominal aorta and inferior vena cava.

Additional windows include the suprasternal window, which can be used for examination of the aorta, and the right parasternal window, which is useful for ascending aorta examination.

3. BACKGROUND

Right ventricular failure is a very common early complication after LVAD implantation, however it is not yet possible to conclude, which variables are the most influential in risk estimation and complication prediction.

The aim of this study was to identify and obtain clinical, hemodynamic and echocardiographic parameters and derived models that could successfully predict RVF in LVAD recipients.

4. METHODS

Preoperative assessment of echocardiographic and RHC parameters was done for 40 consecutive patients at the University Hospital Centre Zagreb (36 male and 4 female, mean age 60.4 ± 6.9 years), who have undergone continuous flow LVAD implantation (80% of patients received HeartMate II/III and 20% of patients HeartWare).

Demographic data were obtained for all the patients and those included: age, gender, etiology of the disease (which was further divided into four subcategories: dilated cardiomyopathy (CMP), ischemic CMP, left ventricular noncompaction (LVNC), acute myocardial infarction (MI), previous cardiac surgery with or without concomitant aortic valve repair (AVR) and body surface area (BSA) (Table 1).

Echocardiographic parameters were obtained through a complete standard transthoracic echocardiographic examination [13], which still remains the golden standard for assessment of left and right ventricular systolic and diastolic function as well as evaluation of pressures in pulmonary artery [2]. Upon echocardiographic examination of the right heart, it is important to evaluate both – function and structure of the right ventricle as well as right atrium. The best indicator of right ventricular systolic function is tricuspid annular plane systolic excursion (TAPSE), TAPSE lower than 17 mm indicates systolic dysfunction of the right ventricle [13]. Right ventricular fractional area change (RVFAC) represents another important parameter for evaluation of right ventricular systolic function and is calculated as a difference of right ventricular end diastolic area and right ventricular end systolic area, being further divided by right ventricular end diastolic area times one hundred [14]. For the purpose of our studies of RV geometry, we have defined the right ventricular asymmetry (RVA) index as a ratio of the difference of the medial and lateral portion of RV area in relation to total RV area at end diastole (Figure 1.).

Parameters obtained with echocardiographic examination of the right heart for this study were: right ventricular internal dimension in diastole (RVIDd), right ventricle (RV) length, right atrium volume indexed to BSA (RAVol/BSA), TAPSE, RVFAC and RVA index.

Other parameters were obtained through Swan-Ganz heart catheterization. During the Swan – Ganz catheterization, a thin catheter is positioned in the subclavian, femoral or jugular vein through a vascular sheath introduced by means of the Seldinger technique. The catheter is further advanced to the right heart, followed by the pulmonary artery, up to the wedge position. In this study, the Swan-Ganz method was used to obtain the following parameters: CI, systolic pulmonary artery pressure (sPAP), diastolic pulmonary artery pressure (dPAP), mean pulmonary artery pressure (mPAP), pulmonary capillary wedge pressure (PCWP), peripheral vascular resistance (PVR), transpulmonary gradient (TPG), right atrial pressure (RAP) and right ventricular stroke work index (RVSWI).

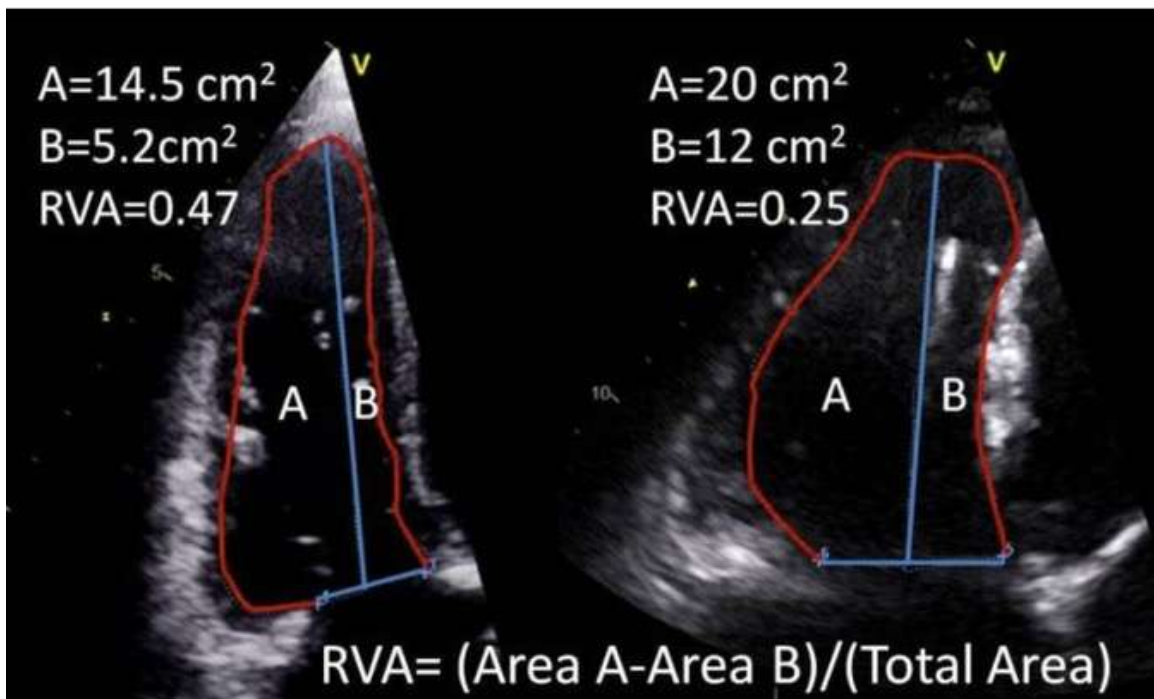


Figure 1. Right ventricular asymmetry (RVA) index defined as a ratio of the difference of the medial (B) and lateral (A) portion of the RV area in relation to total RV area at end diastole.

The patients were divided into two groups, according to the development of postoperative RV failure (defined by the INTERMACS criteria). The RV failure group consisted of 6 patients, while the remaining 34 patients were within the non-RV failure group.

The statistic analysis was performed using Microsoft Office Excel and SPSS programs. For group comparison Pearson chi square and Student's t-test were used. The p value <0.05 was deemed statistically significant. Fisher's exact test was used for the tables of contingency, while the ROC curves were used for the calculation of the AUC.

5. RESULTS

The demographic characteristics of both groups are presented in Table 1. Six out of forty patients (15%) developed RV failure after LVAD implantation. Mean age of patients in RV failure group was 58.7 ± 6.0 years. In this group, there were 5 male patients and 1 female patient. Cardiac disease etiology varied within the group: one patient had dilated CMP and five patients had ischemic CMP. Two out of six patients had a history of previous cardiac surgery, but none of them had the concomitant AVR procedure done during LVAD implantation. Average BSA within the group was 2.1 ± 2.7 m².

Thirty-four out of forty patients (85%) did not develop RV failure after LVAD implantation. Mean age of the Non-RV failure group was 61.5 ± 5.5 years. In this group there were 31 male patients and 3 female patients. The leading cause of cardiac disease was ischemic CMP (68%), followed by dilated CMP (27%) and LVNC (5%). Five patients had a history of previous cardiac surgery, and five patients had the concomitant AVR procedure performed. Average BSA for non-RV failure group was 2.0 ± 0.2 m².

Table 1. Demographic characteristics of studied population

Characteristic	RV failure	Non-RV failure	p value
Number of pts	6/40 (15%)	34/40 (85%)	
Age	58.7±6.0	61.5±5.5	0.485
Gender			
- male	5/6 (83%)	31/34 (91%)	
- female	1/6 (17%)	3/34 (9%)	
Disease etiology:			
- dilated CMP	1/6 (17%)	9/34 (27%)	
- ischemic CMP	5/6 (83%)	23/34 (68%)	
- LVNC	0/6	2/34 (6%)	
- acute MI	0/6	0/34	
Previous cardiac surgery	2/6 (33%)	5/34 (15%)	
Concomitant AVR	0/6	5/34 (15%)	
BSA (m ²)	2.1±2.7	2.0±0.2	0.493

Table 2 compares echocardiographic data for both groups of patients.

Echocardiographic evaluation of patients in the RV failure group showed that average RVIDd was enlarged at 43.8±5.7 mm, average RV length was 85±9.0 mm and RAVol/BSA ratio was calculated to be 53.6±18.3 ml/m², also indicating RA dilatation. Right ventricular systolic function was also on average mildly reduced: TAPSE was 12.3±3.1 mm, and the average value of right ventricular fractional area was 24.3±11.7. The RVA index was calculated to be 0.2±0.1.

In the non-RV failure group, the measurements of RA and RV geometry also demonstrated an enlargement of these cavities: the average RVIDd was 40.8±7.0 mm. This group had an average RV length of 88.4±11.8 mm. RAVol/BSA ratio was

calculated and it was 39.7 ± 13.8 ml/m². TAPSE was 14.6 ± 4.3 mm. RVFAC was also reduced at 25.9 ± 7.4 %. Average value of RVA index for this group was 0.4 ± 0.1 .

The only parameter that showed statistically significant difference ($p=0.0001$) between the two groups was the RVA index, being significantly higher (indicating greater RV asymmetry) in the group of patients without RV failure, than in the RV failure group.

Table 2. Echocardiography data pertaining to right ventricular morphology and function

Parameter	RV failure	Non-RV failure	p value
Number of pts	6/40 (15%)	34/40 (85%)	
RVIDd (mm)	43.8 ± 5.7	40.8 ± 7.0	0.286
RV length (mm)	85 ± 9.0	88.4 ± 11.8	0.440
RAVol/BSA (ml/m ²)	53.6 ± 18.3	39.7 ± 13.8	0.127
TAPSE (mm)	12.3 ± 3.1	14.6 ± 4.3	0.163
RVFAC (%)	24.3 ± 11.7	25.9 ± 7.4	0.762
RVA index	0.2 ± 0.1	0.4 ± 0.1	0.0001

Table 3 summarizes the data obtained during right heart catheterization. CI was similar in the RV failure and in the non-RV failure group (1.6 ± 0.4 vs. 1.8 ± 0.4 L/min/m² respectively). There were no statistically significant differences in sPAP, mPAP, PCWP, PVR, TPG, RVSWI between the two groups.

The only variable that was statistically significantly different between the two groups was right atrial pressure. In the RV failure group RAP was 16.7±4.1 mmHg and in the non-RV failure group it was 9.7±5.2 mmHg (p=0.006).

Table 3. Right heart catheterisation data

Parameter	RV failure	Non-RV failure	p value
CI (L/min/m ²)	1.6±0.4	1.8±0.4	0.295
sPAP (mmHg)	74±19.1	63.1±18.7	0.231
mPAP (mmHg)	47.3±6.7	41.6±12.4	0.145
PCWP (mmHg)	27.2±5.2	26.5±8.5	0.862
PVR (dynes/cm ²)	6.5±3.0	4.5±2.2	0.188
TPG (mmHg)	20.2±9.0	15.1±6.4	0.241
RAP (mmHg)	16.7±4.1	9.7±5.2	0.006
RVSWI (g/m ² /beat)	10.8±6.6	9.4±2.4	0.667

Table 4 shows how various Swan-Ganz and echocardiographic variables alone or in combination perform in the prediction of post-LVAD RVF. The combination of RAVol/BSA, RVA and PVR, as well as the combination RAVol/BSA, RVA and TPG showed the optimal combination of high specificity (100%) and sensitivity (67%), with the highest Receiver-operating characteristics area under curve (ROC AUC) of 0.833.

Conversely, the markers routinely used to assess RV function, such as FAC and TAPSE, failed to predict the development of RV failure after LVAD implantation.

Table 4. Swan-Ganz and echocardiographic variables in the prediction of post-LVAD RV failure

Parameter	ROC AUC	Sensitivity	Specificity	p value (chi square)
RAVol/BSA + RVA	0.778	67%	89%	0.006
RAVol/BSA + RVA + CI	0.713	50%	93%	0.022
RAVol/BSA + RVA + sPAP	0.815	67%	96%	0.001
RAVol/BSA + RVA + CVP	0.713	50%	93%	0.026
RAVol/BSA + RVA + PVR	0.833	67%	100%	<0.0001
RAVol/BSA + RVA + TPG	0.833	67%	100%	<0.0001
FAC	0.38	50%	26%	0.357
TAPSE	0.694	83%	56%	0.182
TAPSE + FAC	0.441	33%	55%	0.680

6. DISCUSSION

Patients with advanced heart failure have two main treatment options. The first option is heart transplantation and the second is the implantation of an LVAD. Right ventricular failure is one of the most common complications in the immediate postoperative period following LVAD implantation, therefore preoperative evaluation of patients and postoperative risk assessment are of crucial importance. However, numerous factors and comorbidities influence the final outcome in each individual, which encumbers the prediction of right ventricular failure. Unfortunately, it is not yet clear which of the clinical, echocardiographic or hemodynamic variables significantly impacts outcome prediction.

Many studies have been performed in order to predict RVF failure after LVAD implantation. Study by Argiriou *et al.* [15] suggested that risk for developing RVF is low in the setting of the following combination of hemodynamic parameters: CVP ≤ 8 mmHg, PCWP ≤ 18 mmHg, CVP/PCWP ≤ 0.66 , PVR < 2 dynes/cm² and RVSWI ≥ 400 mmHg mL/m². Raina *et al.* [16] compared echocardiographic parameters between patients who developed RVF and patients who did not develop RVF after implantation of LVAD. The authors concluded that preoperative evaluation of RVFAC (which was significantly lower in patients who developed RVF compared to patients without RVF), RAP (which was significantly higher in RVF group of patients), LAV index (that was lower in RVF group of patients) could predict the likelihood of postoperative RVF. Puwanant *et al.* [17] compared echocardiographic parameters of the right ventricle between two groups of patients – group who developed RVF and group without RVF. Parameters obtained with echocardiographic examination included tricuspid annular motion, RVFAC, RAVol index, hepatic vein Doppler velocities, RV systolic pressures, RV index of myocardial performance and tricuspid regurgitation severity. The study displayed that patients who developed postoperative RVF had lower preoperative tricuspid annular motion and higher RV systolic pressures. Other parameters showed no significant difference between the two groups. The authors concluded that tricuspid annular motion can be considered a predictor of RVF after LVAD implantation.

Echocardiographic parameters of RV geometry and function and hemodynamic data obtained by right heart catheterization are complementary methods routinely used in the preoperative assessment of LVAD candidates. Thus, the aim of this study was to determine which parameter or which combination of parameters obtained by these two methods would show the greatest accuracy and reliability for predicting right ventricular failure in left ventricular assist device recipients. Based on our data, the routinely used echocardiographic and RHC parameters have failed to show statistically significant differences among patients with and without RV failure. The exception was the novel marker of RV geometry, the RVA index, which was significantly higher (indicating greater RV asymmetry) in the group of patients without RV failure than in the RV failure group (0.4 ± 0.1 vs 0.2 ± 0.1 respectively, $p<0.0001$), as well as the RAP, which was higher in the RV failure group (16.7 ± 4.1 vs. 9.7 ± 5.2 mmHg, respectively, $p=0.006$).

Furthermore, the combination of right atrial volume indexed to BSA, right ventricular asymmetry and peripheral vascular resistance (RAVol/BSA + RVA + PVR, $p<0.0001$) as well as right atrial volume indexed to BSA, right ventricular asymmetry and transpulmonary gradient (RAVol/BSA + RVA + TPG, $p<0.0001$) were detected as superior predictors of post-LVAD right ventricular failure, performing better than e.g. the combination of TAPSE and FAC.

We acknowledge that our study is limited by a small number of patients. However, it provides a basis for future research using a combination of echocardiographic parameters of right heart geometry and hemodynamic parameters of right ventricular loading conditions which may prove to be reliable predictors of right ventricular failure following LVAD implantation.

7. CONCLUSION

Left ventricular assist device use increases with every day in medical practice. LVADs can be used as a destination therapy, where LVAD is used as an alternative to heart transplantation, as a bridge to transplant therapy, where mechanical circulatory support is used until the patient receives a donor heart, or as bridge to recovery therapy, where LVAD is used for chronically ill patients, that will after LVAD placement recover sustainable myocardial function. The selection of patients for the LVAD implantation is difficult, since many factors such as age and comorbidity influence the health outcome.

Despite the limitations of this study, due to a small number of enrolled patients (40 patients), it was possible to demonstrate that echocardiographic parameters of RV and RA geometry (the RVA index and RA volume indexed to BSA) used in combination with RHC parameters of RV afterload (such as the PVR or TPG) may be accurate and reliable predictors of potential right ventricular failure after implantation of LVADs.

8. ACKNOWLEDGMENTS

I would like to thank Assistant professor Maja Čikeš, MD, PhD, for her unrelentless guidance, help, expertise, and kindness. I would also like to express my gratitude to dr. Nina Jakuš, dr. Ivo Planinc and dr. Dora Fabijanović from the Department of Cardiovascular Diseases, University Hospital Centre Zagreb, who have collected and analyzed some of the shown data. I would also like to thank Javni sklad RS za razvoj kadrov in štipendije, for financing my studies.

9. REFERENCES

1. American Heart Association (2015). *Classes of Heart Failure*. Accessed February 2016: <http://goo.gl/dUssv0>.
2. Ponikowski P, Voors AA, Anker SD, Bueno H, Cleland JGF, Coats AJS, Falk V, González-Juanatey JR, Harjola VP, Jankowska EA, Jessup M, Linde C, Nihoyannopoulos P, Parissis JT, Pieske B, Riley JP, Rosano GMC, Ruilope LM, Ruschitzka F, Rutten FH, van der Meer P. *2016 ESC Guidelines for the diagnosis and treatment of acute and chronic heart failure*. 2016, *Eur Heart Journal*, published online, doi:10.1093/eurheartj/ehw128
3. Pepper JR. *Update on Mechanical Circulatory Support in Heart Failure*. *Heart*. 2012;98(8):663-669.
4. Alba AC, Delgado DH. *The Future is Here: Ventricular Assist Devices of the Failing Heart*. *Expert Rev Cardiovasc Ther*. 2009;7(9):1067-77.
5. Kasper DL, Harrison TR (2005). *Harrison's principles of internal medicine*. New York, McGraw-Hill, Medical Pub. Divisio; pages 1916-1919.
6. Yarboro LT, Bergin JD, Kennedy JLW, Ballew CC, Benton EM, Ailawadi, G, Kern JA. *Technique for minimizing and treating driveline infections*. *Annals of Cardiothoracic Surgery*. 2014;3(6);557–562.
7. Eckman PM, John R. *Advances in Mechanical Circulatory Support. Bleeding and Thrombosis in Patients With Continuous-Flow Ventricular Assist Devices*. 2012;125: 3038-3047.
8. Kaddoura S. (2009). *Echo made easy 2nd edition*. London, UK: Churchill Livingstone; pages 10-147.

9. Solomon SD, Louie EK, Schiller NB. *Guidelines for the Echocardiographic Assessment of the Right Heart in Adults: A Report from the American Society of Echocardiography Endorsed by the European Association of Echocardiography, a registered branch of the European Society of Cardiology, and the Canadian Society of Echocardiography*; *J Am Soc Echocardiogr* 2010;23:685-713.
10. Fida N, Loebe M, JD, Guha A. *Predictors and management of right heart failure after left ventricular assist device implantation*. 2015;11(1):18-23.
11. Drakos SG, Kfoury AG, Selzman CH, Verma DR, Nanas JN, Li DY, Stehlik J. *Left ventricular assist device unloading effects on myocardial structure and function: current status of the field and call for action*; *Curr Opin Cardiol*. 2011;26(3): 245–255.
12. Kirklin JK, Naftel DC, Stevenson LW, et al. *INTERMACS database for durable devices for circulatory support: first annual report*. *J Heart Lung Transplant*. 2008;27(10):1065-72.
13. Lang RM, Badano LP, Mor-Avi V, Afilalo J, Armstrong A, Ernande L, Flachskampf FA, Foster E, Goldstein SA, Kuznetsova T, Lancellotti P, Muraru D, Picard MH, Rietzschel ER, Rudski L, Spencer KT, Tsang W, Voigt J-U. *Recommendations for cardiac chamber quantification by echocardiography in adults: an update from the American Society of Echocardiography and the European Association of Cardiovascular Imaging*. *Eur Heart J Cardiovasc Imaging* 2015;16:233–270.
14. Rudski LG, Lai WW, Afilalo J, Hua L, Handschumacher MD, Chandrasekaran K, Solomon SD, Louie EK, Schiller NB. *Guidelines for the echocardiographic assessment of the right heart in adults: a report from the American Society of Echocardiography endorsed by the European Association of Echocardiography, a registered branch of the European Society of Cardiology, and the Canadian Society of Echocardiography*. *J Am Soc Echocardiogr*:2010, 23(7);685-713.

15. Argiriou M, Kolokotron SM, Sakellaridis T, Argiriou O, Charitos C, Zarogoulidis P, Katsikogiannis N, Kougioumtzi I, Machairiotis N, Tsiouda T, Tsakiridis K, Zarogoulidis K. *Right heart failure post left ventricular assist device implantation. J Thorac Dis. 2014; 6(Suppl 1): S52–S59.*
16. Raina A, Seetha Rammohan HR, Gertz ZM, Rame JE, Woo YJ, Kirkpatrick JN. *Postoperative right ventricular failure after left ventricular assist device placement is predicted by preoperative echocardiographic structural, hemodynamic, and functional parameters. J Card Fail. 2013 Jan;19(1):16-24.*
17. Puwanant S, Hamilton KK, Klodell CT, Hill JA, Schofield RS, Cleeton TS, Pauly DF, Aranda JM Jr. *Tricuspid annular motion as a predictor of severe right ventricular failure after left ventricular assist device implantation. J Heart Lung Transplant. 2008;27(10):1102-7.*

10. BIOGRAPHY

I was born on 20.4.1991 in Slovenj Gradec, Slovenia. I have finished primary school and high school (Gimnazija Velenje) in Velenje. In September 2010 I enrolled in the first year of Medical Studies in English program at the School of Medicine, University of Zagreb. During my studies I received The Dean's commendation for distinguished academic success, the best student of Medical Studies in English program in academic year 2015/2016. For two years I have worked as a student teaching assistant at the Department of cardiovascular diseases, at the University Hospital Centre Zagreb. For two years I was a member and a leader of the executive board of Student section of cardiology, an active member of EMSA (European Medical Student Association) as well as a member of the Student Section of the Croatian Medical Association. Since November 2014 I am also ILS (immediate life support) certified. In April 2016 I had an amazing opportunity to do my cardiology clinical rotations at the KABEG Klinikum am Wörthersee at the 2. Medizinische Abteilung. For one month I volunteered at the Department of General and abdominal surgery at Splošna bolnišnica Slovenj Gradec. I will graduate in July 2016.