

# Ekvivalent: Non-Hodgkinov limfom frontalnog sinusa - prikaz slučaja i pregled literature

---

**Doko, Sandra**

**Professional thesis / Završni specijalistički**

**2023**

*Degree Grantor / Ustanova koja je dodijelila akademski / stručni stupanj:* **University of Zagreb, School of Medicine / Sveučilište u Zagrebu, Medicinski fakultet**

*Permanent link / Trajna poveznica:* <https://um.nsk.hr/um:nbn:hr:105:107723>

*Rights / Prava:* [In copyright](#)/[Zaštićeno autorskim pravom.](#)

*Download date / Datum preuzimanja:* **2024-07-09**



*Repository / Repozitorij:*

[Dr Med - University of Zagreb School of Medicine Digital Repository](#)



Sveučilište u Zagrebu  
Medicinski fakultet

Sandra Doko

NON-HODGKINOV LIMFOM FRONTALNOG  
SINUSA – PRIKAZ SLUČAJA I PREGLED  
LITERATURE

Završni specijalistički rad

Zagreb, kolovoz, 2023. godine

Ovaj rad je ekvivalent završnog rada na poslijediplomskom specijalističkom studiju Otorinolaringologija u akademskoj godini 2018./2019. Rad je objavljen u časopisu Medica Jadertina u prosincu 2022. godine.

Doko S, Kelava I, Penezić A, Grgić MV. Non-Hodgkin's lymphoma of the frontal sinus. Case report and literature review. MedicaJadertina. 52(3), 207-214.

<https://doi.org/10.57140/mj.52.3.5>

Naziv ustanove u kojoj je rad izrađen: Odjel kirurgije glave i vrata, Zavod za kiruršku onkologiju, Klinika za tumore, KBC Sestre Milosrdnice.

Voditelj rada: doc. dr. sc. Marko Velimir Grgić, dr. med.

Redni broj rada:

## Non-Hodkin's lymphoma of the frontal sinus. Case report and literature review

*Non-Hodgkinov limfom frontalnog sinusa. Prikaz slučaja i pregled literature*

**Sandra Doko, Iva Kelava, Ana Penezić, Marko Velimir Grgić\***

---

### Summary

Primary frontal sinus Non-Hodgkin's lymphoma (NHL) is an extremely rare condition with 20 cases published in the existing literature to date. We describe a 64-year-old patient who presented with right orbital pain, severe headache and diplopia. He was initially diagnosed with acute exacerbation of chronic rhinosinusitis and responded well to antibiotic treatment, but his symptoms returned. The diagnosis of frontal sinus NHL was made only after functional endoscopic frontal sinus surgery was performed in general anaesthesia. A tumor mass, which was filling the entire right frontal sinus, was completely removed and sent to histopathological examination. The patient was finally diagnosed with diffuse large B-cell lymphoma of the frontal sinus and referred to the haematology department for tumor staging and chemotherapy. This case emphasizes the importance of early clinical suspicion and diagnosis, which leads to early treatment and better prognosis.

**Key words:** frontal sinus, paranasal sinus, diffuse large B-cell lymphoma, non-Hodgkin's lymphoma

---

### Sažetak

Primarni Non-Hodgkinov limfom (NHL) frontalnog sinusa izrazito je rijedak, s do sada opisanih 20 slučajeva u literaturi. Prikazujemo 64-godišnjeg bolesnika koji se prezentirao simptomima desnostrane orbitalne boli i jake glavobolje s dvoslikama. Najprije je postavljena dijagnoza akutne egzacerbacije kroničnog rinosinuitisa uz dobar odgovor na započetu antibiotsku terapiju, ali i povratak simptoma nakon prekida liječenja. Definitivna dijagnoza Non-Hodgkinovog limfoma frontalnog sinusa postavljena je tek nakon učinjene funkcionalne endoskopske operacije sinusa u općoj anesteziji. Tumorsko tkivo koje je ispunjavalo cijelu desnu polovicu frontalnog sinusa odstranjeno je u cijelosti i poslano na patohistološku analizu. Bolesniku je dijagnosticiran difuzni B-velikostanični limfom frontalnog sinusa nakon čega je upućen na odjel hematologije radi daljnje dijagnostike i liječenja kemoterapijom. Želimo naglasiti važnost rane kliničke sumnje i rane dijagnoze ove bolesti, što doprinosi ranijem početku liječenja i boljoj prognozi.

**Ključne riječi:** frontalni sinus, paranasalni sinus, difuzni B-velikostanični limfom, non-Hodgkinov limfom

*Med Jad 2022;52(3):207-214*

### Introduction

Primary Non-Hodkin's lymphoma (NHL) is rarely extranodal. Common primary extranodal sites

include liver, soft tissue, dura, bone, stomach, intestine and bone marrow.<sup>1</sup>The most frequent sites of NHL of the oral cavity and maxillofacial region are the salivary glands and intraoral mucosa.<sup>2</sup>

---

\* **University hospital center „Sestre milosrdnice“**, University hospital for tumors, Division of head and neck surgery, Department of surgical oncology, Zagreb, Croatia (Sandra Doko, MD); Department of otorhinolaryngology, Zagreb, Croatia (Iva Kelava, MD; PhD Ana Penezić, MD; Prof. Marko Velimir Grgić, MD); **University of Zagreb, School of Medicine** (Prof. Marko Velimir Grgić, MD)

Correspondence address / *Adresa za dopisivanje*: Sandra Doko, MD, Division of head and neck surgery, Department of surgical oncology, University hospital for tumors, University hospital center „Sestre milosrdnice“, Ilica 197, 10 000 Zagreb, Croatia E-mail: [sandra.doko@gmail.com](mailto:sandra.doko@gmail.com)

Received/*Primljeno* 2022-03-22; Revised/*Ispravljeno* 2022-09-20; Accepted/*Prihvaćeno* 2022-09-27

Nasal cavities and paranasal sinuses are rarely affected by primary NHL. The incidence of sinonasal NHL is estimated to be between 0.2% and 2% of all NHL.<sup>3,4</sup> Primary frontal sinus NHL is an extremely rare condition. To the best of our knowledge there are 20 cases of primary frontal sinus NHL published in the worldwide literature to date (Table 1).<sup>5</sup> Nasal cavity and paranasal sinus lymphoma probably arises from lymphoid cells normally found in the submucosa and sinus bone marrow. The majority of sinonasal lymphomas diagnosed in Europe and North America are B-cell neoplasms and the most common lymphoma involving the sinonasal area is diffuse large B-cell lymphoma (DLBCL).<sup>1</sup> T-cell lymphoma is more common in Asia and in some Latin American countries. Signs and symptoms of sinonasal NHL are various and nonspecific which makes the clinical diagnosis very challenging. The diagnosis is confirmed with Computed Tomography (CT), Magnetic Resonance Imaging (MRI) and tumor biopsy. The treatment consists of chemotherapy, sometimes associated with radiotherapy.<sup>4</sup> The aim of this paper is to present our experience with diagnosis and treatment of a B-cell type frontal sinus NHL and to review the currently available literature.

### Case report

A 64-year-old man with a history of hypertension and glaucoma was referred from an outside institution where he presented with right orbital pain, severe headache and diplopia that lasted for two months. Physical examination was within normal limits. MRI of the head revealed dense opacification of the right frontal sinus as well as signs of chronic inflammatory process of the frontal, sphenoid and right ethmoid sinus. The patient was diagnosed with acute exacerbation of chronic rhinosinusitis and treated conservatively. He received intravenous clindamycin and methylprednisolone for seven days. The symptoms completely resolved and the patient was discharged to home. After seventeen days, the patient was admitted to our hospital due to a sudden onset of severe headache with right upper lid swelling and diplopia in upward and downward gaze. Symptoms reoccurred several days after discharge from the outside institution. Nose endoscopy showed mucosal oedema bilaterally, without discharge. Eye examination revealed redness and oedema of the right eyelid with conjunctival chemosis and proptosis. There was no restriction of eye movements, but the patient had diplopia in the upward and downward gaze. Ophthalmoscopy was within normal limits. CT scan showed a tumor mass filling the right frontal

sinus (Fig. 1a), with no signs of acute inflammation of the sphenoid, ethmoid or maxillary sinus (Fig. 1b). Acute exacerbation of chronic rhinosinusitis was suspected and functional endoscopic frontal sinus surgery was performed in general anesthesia. After the right frontal recess was widened, a tumor mass was visualized filling the entire right frontal sinus (Fig. 2).

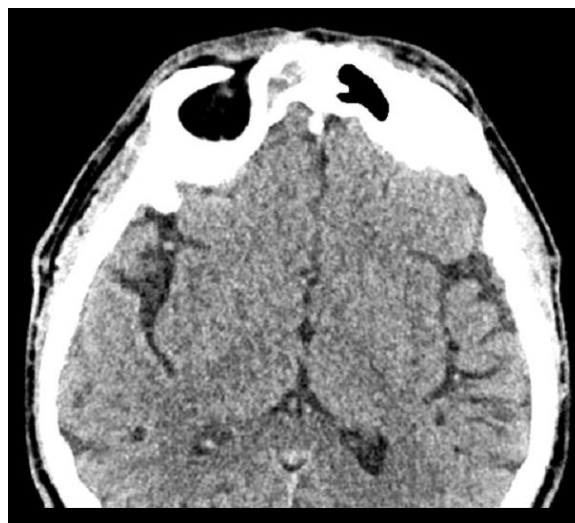


Figure 1a CT image of the patient in axial plane. Tumor mass is located in the right frontal sinus. *Slika 1a. CT slika bolesnika u aksijalnoj ravnini. Tumorska masa nalazi se u desnom frontalnom sinusu.*

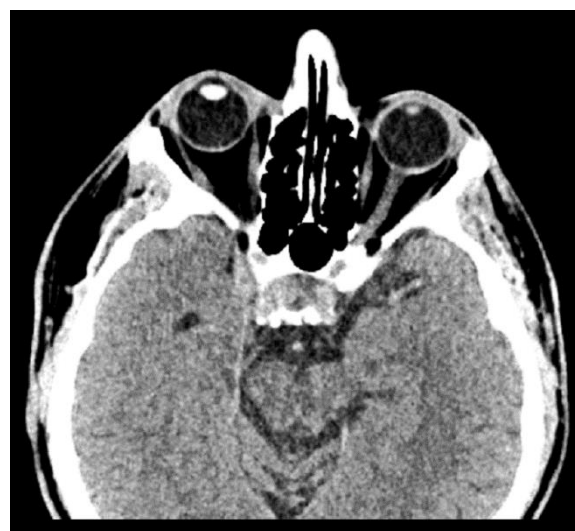

Figure 1b CT image of the patient in axial plane. There were no signs of inflammation of the sphenoid and ethmoid sinus. *Slika 1b. CT slika bolesnika u aksijalnoj ravnini. Nije bilo znakova upale sfenoidnog i etmoidnog sinusa.*

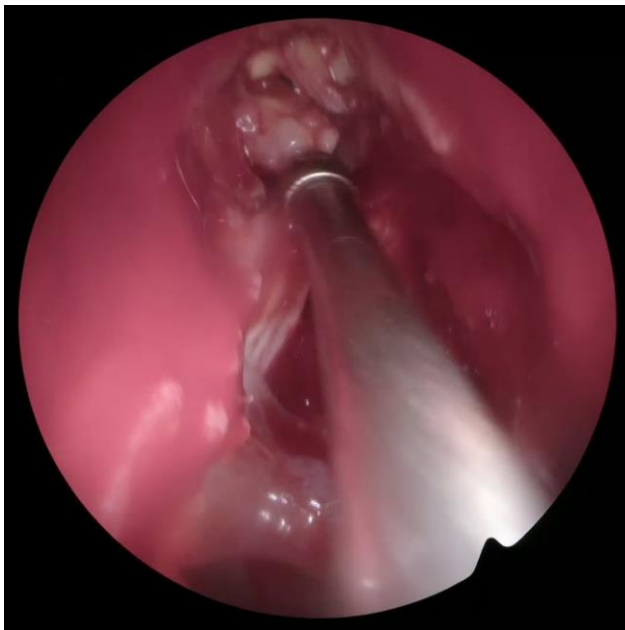

Figure 2 Intraoperative photo of the functional endoscopic frontal sinus surgery. A tumor mass is filling the entire right frontal sinus.

*Slika 2. Intraoperativna fotografija funkcionalne endoskopske operacije frontalnog sinusa. Tumorska masa ispunjava cijeli desni frontalni sinus.*

The tumor was completely removed and sent to histopathological examination. Histopathologic analysis with hematoxylin and eosin staining revealed nodular infiltration of atypical and large-sized lymphocytes. Immunohistochemical staining showed that the neoplastic cells were positive for CD20, BCL2, BCL6 and CD10 but negative for CD3, HMB 45 and CKPAN. The Ki-67 labeling index was 95%. The patient was diagnosed with frontal sinus NHL (DLBCL, germinal center B-cell subtype) and referred to the hematology department of our hospital for tumor staging and chemotherapy. Further investigations which included CT scans of the neck, thorax, abdomen and pelvis did not reveal any disseminated disease. He was at stage IE according to the Ann Arbor staging system. The patient underwent chemotherapy and immunotherapy following R-CHOP (rituximab, cyclophosphamide, doxorubicine, vincristine and prednisolone) protocol with a complete response. The patient was without any symptoms fourteen months after the treatment. Follow-up CT revealed no signs of the disease in frontal sinus.

### Discussion and literature review

Sinonasal NHL is a rare condition. According to literature, it accounts for 0.2% to 2% of all NHL.<sup>3,4</sup>

The most common site of origin of the sinonasal NHL is maxillary sinus, followed by the nasal cavity and the ethmoid sinuses, while frontal sinus involvement is usually due to the secondary extension from other sinuses.<sup>6</sup> Primary involvement of the frontal sinus is very rare with only 20 cases published in the existing literature to date (Table 1). According to previous reports, primary frontal NHL are usually localized or locally advanced. Dissemination of the disease from this site was rarely reported.<sup>7</sup>

There are several problems that prevent early recognition of frontal sinus NHL. The patient can be asymptomatic for a long period of time. When the symptoms develop, they are nonspecific and they typically overlap with the symptoms of chronic frontal rhinosinusitis. According to literature, the most common symptom of the frontal sinus NHL is headache, followed by nasal obstruction, periorbital swelling, epistaxis and facial swelling.<sup>4</sup> In the study on 22 patients with sinonasal NHL, the mean interval between symptom onset and diagnosis was four months.<sup>8</sup> Our patient was diagnosed with frontal sinus NHL three months after the first symptom. He had severe headache, diplopia and right orbital pain which are symptoms comparable to those described in literature. He presented without any B symptoms (fever, night sweats and loss of body weight), which is in correlation with tumor stage. The presence of B symptoms is usually a sign of distant disease and worsens the prognosis. The ENT examination of our patient was within normal findings. This was expected since nasal endoscopy can only reveal gross tumor that had already extended into the nasal cavity. The CT scan and MRI were nonspecific in our patient. The CT scan showed complete obliteration of the right frontal sinus, without any bone destruction or invasion of adjacent structures. According to literature, common sinonasal lymphoma CT finding is a homogenous, bulky mass with high opacification. Sinonasal lymphomas frequently show both infiltrative and permeative bony invasion and destruction. Necrotic areas within the tumor can occasionally be observed. Sinonasal NHL often show isointensity on T1 weighted images and mild hyperintensity on T2 weighted images. However, neither CT nor MRI findings are specific enough for certain diagnosis of lymphoma.<sup>9</sup> To obtain the definitive diagnosis, biopsy and histopathologic analysis is required. DLBCL is the most common subtype of NHL worldwide. According to literature, more than 60% of DLBCL patients can be cured with R-CHOP immunochemotherapy, but patients with treatment failure after R-CHOP often have a poor outcome.<sup>10</sup>

Table 1 Primary involvement of the frontal sinus published in the current literature.  
 Tablica 1. Primarna zahvaćenost frontalnog sinusa objavljena u aktualnoj literaturi.

	Study/ <i>studija</i>	Pathology <i>Patologija</i>	Age, y/Sex <i>Dob,</i> <i> spol</i>	Presenting signs / <i>Znakovi bolesti</i>	Type of report <i>Vrsta</i> <i>izvješća</i>	Stage <i>Stadij</i>	Treatment <i>Liječenje</i>	Prognosis <i>Prognoza</i>
1	Duncavage et al <sup>11</sup>	NA <i>Nije dostupno</i>	NA <i>Nije dostupno</i>	Facial swelling / <i>Oticanje lica</i>	Case series <i>Seriya</i> <i>slučajeva</i>	IVE	NA <i>Nije dostupno</i>	NA <i>Nije dostupno</i>
2	Burres et al <sup>12</sup>	DLBCL <i>difuzni</i> <i>velikostanični</i> <i>limfom</i>	43/F	Frontal headache, nasal drainage <i>Frontalna glavobolja, nosna drenaža</i>	Case report <i>Izvješće o</i> <i>slučaju</i>	IE	Chemotherapy, surgery <i>Kemoterapija, kirurški</i> <i>zahvat</i>	NED at 2 mo <i>Nema dokaza</i> <i>bolesti u 2 mj.</i>
3	Frierson et al <sup>13</sup>	NA <i>Nije dostupno</i>	NA <i>Nije dostupno</i>	NA <i>Nije dostupno</i>	Case series <i>Seriya</i> <i>slučajeva</i>	NA <i>Nije dostupno</i>	NA <i>Nije dostupno</i>	NA <i>Nije dostupno</i>
4	Cooper and Ginsberg <sup>14</sup>	DLBCL <i>difuzni</i> <i>velikostanični</i> <i>limfom</i>	60/F	Enlarging nodule on nose <i>Povećanje čvorića na nosu</i>	Case series <i>Seriya</i> <i>slučajeva</i>	IE	Chemotherapy, radiotherapy <i>Kemoterapija,</i> <i>radioterapija</i>	NED at 20 mo <i>Nema dokaza</i> <i>bolesti u 20 mj.</i>
5	Spiro et al <sup>15</sup>	NA <i>Nije dostupno</i>	NA <i>Nije dostupno</i>	NA <i>Nije dostupno</i>	Case series <i>Seriya</i> <i>slučajeva</i>	NA <i>Nije dostupno</i>	NA <i>Nije dostupno</i>	NA <i>Nije dostupno</i>
6	el-Hakim et al <sup>16</sup>	DLBCL	58/M	Eyelid edema, frontal headaches, epistaxis, nasal obstruction <i>Edem očnih kapaka, frontalne glavobolje,</i> <i>epistaksa, nazalna opstrukcija</i>	Case report <i>Izvješće o</i> <i>slučaju</i>	IE	Chemotherapy, sinus surgery <i>Kemoterapija, kirurški</i> <i>zahvat sinusa</i>	NED at 3 mo <i>Nema dokaza</i> <i>bolesti u 3 mj.</i>
7	Hatta et al <sup>17</sup>	NA <i>Nije dostupno</i>	NA <i>Nije dostupno</i>	NA <i>Nije dostupno</i>	Case series <i>Seriya</i>	NA <i>Nije dostupno</i>	NA <i>Nije dostupno</i>	NA <i>Nije dostupno</i>

<i>slučajeva</i>								
8	Shohat et al <sup>18</sup>	DLBCL <i>difuzni velikostanični limfom</i>	83/M	Pain, nasal discharge, headache, nasal bleeding <i>Bol, iscjedak iz nosa, glavobolja, krvarenje iz nosa</i>	Case series <i>Serijski slučajevi</i>	IIIE	Chemotherapy, radiotherapy <i>Kemoterapija, radioterapija</i>	NA <i>Nije dostupno</i>
9	Neves et al <sup>19</sup>	DLBCL <i>difuzni velikostanični limfom</i>	43/M	Frontal headaches, bulging eyelid <i>Frontalne glavobolje, ispupčen kapak</i>	Case report <i>Izveštaje o slučaju</i>	NA <i>Nije dostupno</i>	NA <i>Ne primjenjuje</i>	DOD; NA <i>Smrt uslijed bolesti</i> <i>Nije dostupno</i>
10	Nemet et al <sup>20</sup>	DLBCL <i>difuzni velikostanični limfom</i>	84/M	Nontender periorbital swelling <i>Neosjetljivo periorbitalno oticanje</i>	Case report <i>Izveštaje o slučaju</i>	IE	Steroids, radiotherapy <i>Steroidi, radioterapija</i>	DOD at 9 mo <i>Umri od bolesti unutar 9 mjeseci</i>
11	Chain and Kingdom <sup>21</sup>	DLBCL <i>difuzni velikostanični limfom</i>	55/M	Pain and swelling of forehead <i>Bol i oticanje čela</i>	Case report <i>Izveštaje o slučaju</i>	IIEA	Chemotherapy, radiotherapy <i>Kemoterapija, radioterapija</i>	NED at 18 mo <i>Nema dokaza bolesti u 18 mj.</i>
12	Kim et al <sup>22</sup>	DLBCL	42/M	Multiple cranial nerve palsies <i>Višestruke paralize kranijalnih živaca</i>	Case report <i>Izveštaje o slučaju</i>	IVE	Chemotherapy, stem cell therapy <i>Kemoterapija, terapija matičnim stanicama</i>	NED at 50 mo <i>Nema dokaza bolesti u 50 mj.</i>
13	Wong et al <sup>7</sup>	DLBCL	61/F	Enlarging forehead <i>Povećanje čela</i>	Case report <i>Izveštaje o slučaju</i>	NA <i>Nije dostupno</i>	Chemotherapy <i>Kemoterapija</i>	NA <i>Nije dostupno</i>
14	Philip et al <sup>23</sup>	NA <i>Nije dostupno</i>	NA <i>Nije dostupno</i>	NA <i>Nije dostupno</i>	Case report <i>Izveštaje o slučaju</i>	NA <i>Nije dostupno</i>	NA <i>Nije dostupno</i>	NA <i>Nije dostupno</i>
15	Arnautović et al <sup>4</sup>	DLBCL <i>difuzni velikostanični limfom</i>	53/M	Headaches, dizziness, eye tenderness, nasal congestion <i>Glavobolje, vrtoglavica, osjetljivost očiju, začepjenost nosa</i>	Case report <i>Izveštaje o slučaju</i>	IE	Surgery, chemotherapy <i>Kirurški zahvat, kemoterapija,</i>	NED at 12 mo <i>Nema dokaza bolesti u 12 mj.</i>



16	Yang JP et al <sup>24</sup>	DLBCL <i>difuzni velikostanični limfom</i>	43/M	Swelling of forehead, headaches <i>Oticanje čela, glavobolje</i>	Case report <i>Izvešće o slučaju</i>	IE	Surgery, chemotherapy, immunotherapy <i>Kirurški zahvat, kemoterapija, imunoterapija</i>	NED at 24 mo <i>Nema dokaza bolesti u 12 mj.</i>
17	Nagafuji et al <sup>5</sup>	DLBCL <i>difuzni velikostanični limfom</i>	67/M	Diplopia, upper-lid swelling <i>Diplopija, oticanje gornjeg kapka</i>	Case report <i>Izvešće o slučaju</i>	II	Surgery, chemotherapy, immunotherapy <i>Kirurški zahvat, kemoterapija, imunoterapija</i>	NED at 12 mo <i>Nema dokaza bolesti u 12 mj.</i>
18	Yoon et al <sup>25</sup>	DLBCL <i>difuzni velikostanični limfom</i>	46/M	Pain and swelling of forehead, ptosis <i>Bol i oticanje čela, ptoza</i>	Case report <i>Izvešće o slučaju</i>	II	Antiretroviral therapy, chemotherapy <i>Antiretrovirusna terapija, kemoterapija</i>	DOD at 2 we <i>Umrli od bolesti unutar 2 tjedna</i>
19	Yang L et al <sup>26</sup>	DLBCL <i>difuzni velikostanični limfom</i>	65/M	Orbital mass, ptosis <i>Orbitalna masa, ptoza</i>	Case report <i>Izvešće o slučaju</i>	II	Chemotherapy, radiotherapy, immunotherapy <i>Kemoterapija, radioterapija, imunoterapija</i>	NED at 6 mo <i>Nema dokaza bolesti u 6 mj.</i>
20	Kamboj et al <sup>27</sup>	DLBCL <i>difuzni velikostanični limfom</i>	73/M	Diplopia, upper-lid swelling <i>Diplopija, oticanje gornjeg kapka</i>	Case report <i>Izvešće o slučaju</i>	IE	Surgery, chemotherapy, immunotherapy <i>Kirurški zahvat, kemoterapija, imunoterapija</i>	NA <i>Nije dostupno</i>
21	Doko et al (this report)	DLBCL <i>difuzni velikostanični limfom</i>	64/M	Headache, diplopia, orbital pain <i>Glavobolja, diplopija, bol u orbiti</i>	Case report <i>Izvešće o slučaju</i>	IE	Surgery, chemotherapy, immunotherapy <i>Kirurški zahvat, kemoterapija, imunoterapija</i>	NED at 14 mo <i>Nema dokaza bolesti u 14 mj.</i>

Source: Table modified from Khan et al.<sup>4</sup>

Izvor: tablicu prilagodili Khan et al.<sup>4</sup>

Abbreviations: DLBCL, diffuse large B cell lymphoma; DOD, died of illness; NA, not available; NED, no evidence of disease.

Kratice: DLBCL, difuzni velikostanični limfom B stanica; DOD, umrla od bolesti; NA, nije dostupno; NED, nema dokaza bolesti.

## Conclusion

NHL of the frontal sinus is an extremely rare entity. Differentiation from frontal sinus infections and benign tumors is difficult. Lack of symptoms in the early period of the disease, normal physical examination, possible nonspecific CT findings and low incidence make it easy to misdiagnose frontal sinus NHL. As seen in our case, the tumor can cause chronic infection that responds to symptomatic treatment which can mislead the diagnostic process. We emphasize the importance of early clinical suspicion and diagnosis, which leads to early treatment and better prognosis.

## Ethical approval

All procedures performed involving human participants were in accordance with the ethical standards of the institutional and/or national research committee and with the 1964 Helsinki Declaration and its later amendments or comparable ethical standards. Informed consent was obtained from the patient for whom identifying information is included in this case report, and can be obtained if required.

## References

1. Wang J, Sun NC, Weinstein SM, Canalis R. Primary T-cell-rich B-cell lymphoma of the ethmoid sinus. A case report with 5 years of follow-up. *Arch Pathol Lab Med.* 2000;124:1213-6.
2. Triantafyllidou K, Dimitrakopoulos J, Iordanidis F, Gkagkalis A. Extranodal non-hodgkin lymphomas of the oral cavity and maxillofacial region: a clinical study of 58 cases and review of the literature. *J Oral Maxillofac Surg.* 2012;70:2776-85.
3. Fellbaum C, Hansmann ML, Lennert K. Malignant lymphomas of the nasal cavity and paranasal sinuses. *Virchows Arch A Pathol Anat Histopathol.* 1989;414:399-405.
4. Khan NR, Lakičević G, Callihan TR, Burruss G, Arnautović K. Diffuse Large B-Cell Lymphoma of the Frontal Sinus Presenting as a Pott Puffy Tumor: Case Report. *J Neurol Surg Rep.* 2015;76:e23-e27.
5. Nagafuji H, Yokoi H, Ohara A, Fujiwara M, Takayama N, Saito K. Primary diffuse large B-cell lymphoma of the frontal sinus: A case report and literature review. *Radiol Case Rep.* 2018;13:635-639.
6. Freeman C, Berg JW, Cutler SJ. Occurrence and prognosis of extranodal lymphomas. *Cancer.* 1972;29:252-260.
7. Wong EH, Yang WY, Lowe D. Unilateral non-Hodgkin's lymphoma of the frontal sinus presenting as Pott's puffy tumour. *Otolaryngol Pol.* 2013;67:214-7.
8. Lombard M, Michel G, Rives P, Moreau A, Espitalier F, Malard O. Extranodal non-Hodgkin lymphoma of the sinonasal cavities: A 22-case report. *Eur Ann Otorhinolaryngol Head Neck Dis.* 2015;132:271-274.
9. Kawaguchi M, Kato H, Tomita H et al. Imaging Characteristics of Malignant Sinonasal Tumors. *J Clin Med.* 2017;6:116.
10. Sehn LH, Salles G. Diffuse Large B-Cell Lymphoma. *N Engl J Med.* 2021 Mar 4;384:842-858.
11. Duncavage JA, Campbell BH, Hanson GA et al. Diagnosis of malignant lymphomas of the nasal cavity, paranasal sinuses and nasopharynx. *Laryngoscope* 1983;93:1276-1280.
12. Burres SA, Crissman JD, McKenna J, Al-Sarraf M. Lymphoma of the frontal sinus. Case report and review of literature. *Arch Otolaryngol.* 1984;110:270-273.
13. Frierson HF Jr, Mills SE, Innes DJ Jr. Non-Hodgkin's lymphomas of the sinonasal region: histologic subtypes and their clinicopathologic features. *Am J Clin Pathol.* 1984;81:721-727.
14. Cooper DL, Ginsberg SS. Brief chemotherapy, involved field radiation therapy, and central nervous system prophylaxis for paranasal sinus lymphoma. *Cancer.* 1992;69:2888-2893.
15. Spiro JD, Soo KC, Spiro RH. Nonsquamous cell malignant neoplasms of the nasal cavities and paranasal sinuses. *Head Neck.* 1995;17:114-118.
16. El-Hakim H, Ahsan F, Wills LC. Primary non-Hodgkin's lymphoma of the frontal sinus: how we diagnosed it. *Ear Nose Throat J* 2000;79:738, 741-743.
17. Hatta C, Ogasawara H, Okita J, Kubota A, Ishida M, Sakagami M. Non-Hodgkin's malignant lymphoma of the sinonasal tract—treatment outcome for 53 patients according to REAL classification. *Auris Nasus Larynx.* 2001;28:55-60.
18. Shohat I, Berkowicz M, Dori S. et al. Primary non-Hodgkin's lymphoma of the sinonasal tract. *Oral Surg Oral Med Oral Pathol Oral Radiol Endod.* 2004;97:328-331.
19. Neves MC, Lessa MM, Voegels RL, Butugan O. Primary non-Hodgkin's lymphoma of the frontal sinus: case report and review of the literature. *Ear Nose Throat J.* 2005;84:47-51.
20. Nemet AY, Deckel Y, Kourt G. Orbital invasion of frontal sinus lymphoma. *Orbit.* 2006;25:149-151.
21. Chain JR, Kingdom TT. Non-Hodgkin's lymphoma of the frontal sinus presenting as osteomyelitis. *Am J Otolaryngol.* 2007;28:42-45.
22. Kim K, Kim MJ, Ahn S, Bae SY, Kim WS, Yoon JH. Frontal sinus lymphoma presenting as progressive multiple cranial nerve palsy. *Yonsei Med J.* 2011;52:1044-1047.
23. Philip JK, Al-Jassar A, Naquib IS, Usmani S, El-Kabani M, Refaat SM. Primary Non-Hodgkin lymphoma of frontal sinus diagnosed by fine needle aspiration cytology. *Gulf J Oncolog* 2013;1:92-95.
24. Yang JP, Hu CM, Zhong W, Wang ZG. Primary diffuse large B-cell lymphoma of the frontal sinus. *J Biol Regul Homeost Agents.* 2017;31:447-451.

25. Yoon S, Ryu KH, Baek HJ, An HJ, Joo YH. Epstein-Barr virus-positive diffuse large B-cell lymphoma with human immunodeficiency virus mimicking complicated frontal sinusitis: A case report. *World J Clin Cases*. 2021;9:1654-1660.
26. Yang L, Cui Y, Du X, Tan B. Diffuse Large B-Cell Lymphoma of the Frontal Sinus: A Case Report. *Ear Nose Throat J* 2022; doi: 10.1177/01455613221101089.
27. Kamboj A, Hwang C, Mokhtarzadeh A, Harrison AR. Primary Diffuse Large B-Cell Lymphoma of the Frontal Sinus. *Ophthalmic Plast Reconstr Surg* 2022; DOI: 10.1097/IOP.0000000000002223

## Životopis

Sandra Doko, dr.med., rođena je 29. lipnja 1989. godine u Zagrebu. Osnovnu školu i VII. gimnaziju završila je u Zagrebu. Medicinski fakultet Sveučilišta u Zagrebu upisala je 2008. godine te diplomirala 2014. godine. Pripravnički staž odradila je u KBC Sestre milosrdnice 2014.-2015. godine. Od 2015. do 2017. godine radila je u Nastavnom zavodu za hitnu medicinu Grada Zagreba, tijekom čega je položila ALS(Advanced Life Support), ITLS(International Trauma Life Support) i EPALS(European Pediatrics Life Support). Od 2017. do 2022. godine specijalizirala je Otorinolaringologiju u KBC Sestre milosrdnice. Nakon položenog specijalističkog ispita, nastavlja sa radom na Odjelu kirurgije glave i vrata u Klinici za tumore. Primarno područje interesa su joj tumori glave i vratate ultrazvučna dijagnostika i kirurško liječenje bolesti štitnjače. Članica je Hrvatskog društva za otorinolaringologiju i kirurgiju glave i vrata.