

Suicidal chemistry: combined intoxication with carbon monoxide and formic acid

Baković, Marija; Nestić, Marina; Mayer, Davor

Source / Izvornik: **International Journal of Legal Medicine, 2016, 130, 723 - 729**

Journal article, Accepted version

Rad u časopisu, Završna verzija rukopisa prihvaćena za objavljivanje (postprint)

<https://doi.org/doi: 10.1007/s00414-015-1208-0>

Permanent link / Trajna poveznica: <https://um.nsk.hr/um:nbn:hr:105:570368>

Rights / Prava: [In copyright](#)/[Zaštićeno autorskim pravom.](#)

Download date / Datum preuzimanja: **2025-01-09**



Repository / Repozitorij:

[Dr Med - University of Zagreb School of Medicine
Digital Repository](#)





Središnja medicinska knjižnica

Baković M., Nestić M., Mayer D. (2016) *Suicidal chemistry: combined intoxication with carbon monoxide and formic acid*. International Journal of Legal Medicine, 130 (3). pp. 723-9. ISSN 0937-9827

<http://www.springer.com/journal/414>

<http://link.springer.com/journal/414>

The final publication is available at Springer via
<https://doi.org/10.1007/s00414-015-1208-0>

<http://medlib.mef.hr/2719>

University of Zagreb Medical School Repository

<http://medlib.mef.hr/>

Authors:

Bakovic Marija, Nestic Marina, Mayer Davor

Title:

Suicidal chemistry: combined intoxication with carbon monoxide and formic acid

The affiliation and address of the authors:

Institute of Forensic Medicine and Criminalistics, School of Medicine, University

in Zagreb

Šalata 11

10 000 Zagreb

Croatia

Corresponding author:

Mayer Davor

dmayer@mef.hr

telephone: +385 91 5753 105

fax: +385 1 4590 221

Abstract

Herein we present a rare case of suicidal intoxication with carbon monoxide produced via reaction of formic and sulphuric acid with additional toxic effect of formic acid. The deceased was a 22-year-old men found dead in the bathroom locked from the inside. A bucket filled with liquid was found next to him, together with an almost empty canister labeled "Formic acid" and another empty unlabeled canister. The postmortem examination revealed corrosive burns of the face, neck and chest, cherry-pink livor mortis, corrosive injury to the oropharyngeal area and trachea, subpleural petechiae, 100 mL of blood in stomach and superficial erosions of stomach mucosa. Toxicology analysis revealed 30% of carboxyhemoglobin in the femoral blood and the presence of the formic acid in various samples. Quantitative analysis of formic acid was performed by measuring methyl ester derivative of formic acid by using head-space gas chromatography with flame ionization detection. The highest concentration of formic acid was measured in lungs (0.55 g/kg), gastric content (0.39 g/L) and blood (0.28 g/L). In addition, it was established that content of the unlabeled canister had a pH value of 0.79 and contained sulphuric ions. Morphological and toxicology findings suggested that the main route of exposure to formic acid was inhalation of vapors with a possible ingestion of only small amount of liquid acid. The cause of death was determined to be combined intoxication with carbon monoxide and formic acid.

Key words: intoxication, carbon monoxide, formic acid, corrosive injuries

Introduction

Formic acid is an organic acid and the simplest of all carboxylic acids. It is a colorless liquid with a pungent, penetrating odor. It is commercially available as an aqueous solution of various concentrations or as glacial formic acid. Formic acid is used in leather and textile processing, in cleaning processes as a descaler and a biodegradable biocide. Formic acid is highly volatile i. e. it has a great tendency to vaporize – a harmful contamination of the air can be reached rather quickly with evaporation at 20°C [1]. Therefore, it can cause health damage either by direct contact with the liquid formic acid, but, as well, by inhaling the concentrated vapors. Like other organic acids, formic acid has local and remote systemic effects. It belongs to a group of protoplasmic poisons that causes the formation of esters with proteins; it is cytotoxic, especially to red blood cells [2] and acts as an inhibitor of mitochondrial cytochrome oxidase [3]. Both the concentrated liquid formic acid and the concentrated vapors are corrosive to the skin and can cause severe chemical burns [1]. Eye exposure damages the optic nerve and can cause blindness [4]. Inhaled vapors cause irritation or burns in the respiratory tract along with the development of pulmonary edema and chemical pneumonitis [5]. Ingestion causes severe metabolic acidosis, intravascular hemolysis as well as damage to the gastric wall and possible perforations [6].

Sulphuric acid is a strong inorganic acid. In concentrated form it is an oily, colorless and odorless liquid. The major use of sulphuric acid is in the production of fertilizers, chemicals, explosives, motor vehicle batteries, drugs, gasoline and numerous other products [7]. Unlike formic acid, sulphuric acid is not very volatile; it releases toxic and irritating fumes of sulphur oxides only when heated to decomposition [8]. Routes of exposure to sulphuric acid are direct contact to the skin and eyes, ingestion of liquid or inhalation of acid aerosol. Concentrated sulphuric acid is very corrosive and causes chemical burns which are often self-limiting. The damage to the tissue is done via hydrolysis with additional thermal damage, even charring, of the tissue due to dehydration [9]. Like other inorganic acids, sulphuric acid is not absorbed and distributed in the body. Once in contact with the tissue, the acid dissociates rapidly and sulphate anion becomes part of an electrolyte pool and does not play a specific toxicology role [7]. Inhalation of aerosols and mists causes pulmonary edema or ARDS. Ingestion causes hemorrhage, necrosis and perforation in the gastrointestinal tract. Due to the widespread use, chemical burns caused by sulphuric acid are the most commonly encountered [2].

Mixing formic and sulphuric acid causes dehydration of formic acid to gaseous carbon monoxide and the formation of hydrates of sulphuric acid ($\text{HCOOH} + \text{H}_2\text{SO}_4 \rightarrow \text{CO} + \text{H}_2\text{SO}_4 \cdot \text{H}_2\text{O}$). This chemical reaction is used for the production of carbon monoxide in laboratories. In rare cases, the same chemical reaction has been used as a suicide method [10 - 13].

Herein we present a case of carbon monoxide poisoning produced via chemical reaction of formic and sulphuric acid. Besides the toxicity of carbon monoxide, in this presented case, a toxicity of formic acid played an important role as well.

Case presentation

A 22-year-old man was found dead in a bathroom locked from the inside at approximately 3 pm. He was discovered by his sister and neighbor who came to check on him and broke into the bathroom because of a penetrating chemical smell they sensed coming from the inside. He was found lying dead on the floor. They left the bathroom to call the ambulance. Upon the arrival, the emergency medical team took the body out of the bathroom, brought it to open space and applied cardiopulmonary resuscitation. After some time, they were only able to establish death. The sister of the deceased stated that she sensed irritation of her eyes and throat but did not need medical assistance.

The police were also called to the scene to perform the scene investigation. An insight in the police report revealed that the deceased was dressed in a T-shirt and shorts. At the front side of the T-shirt, there were present a couple of small defects of the fabric. During the scene investigation an open plastic 5 L canister, containing approximately 0.1 L of liquid, was found in front of the house. The canister had a label "Formic acid, 85%, made by CIDA SpA Italy". Inside the bathroom there was an empty plastic 5 L canister with no label, together with a 10 L bucket filled by half with unknown fluid. The police noticed that the windows in the bathroom and surrounding rooms were opened. That was done by the parents of the deceased because of the strong chemical smell they sensed upon arrival to the scene.

The body was sent for postmortem examination with a note from the investigators' team that formic acid was found at the scene.

Autopsy findings

The autopsy was performed the following day at 9 am. The most significant findings of the external examination were corrosive injury to the skin and cherry-pink livor mortis at the back of the body. The corrosive burns were located at the face and neck (Figure 1) with a couple of small, spotlike burns at the upper front part of the chest (Figure 2). The burns were mostly superficial and with a discrete but noticeable greenish hue. The borders toward the unburned skin were vague and ill defined. Additionally, small dark brown and black sharply bordered areas of dry skin were diffusely spread on the face. The lips were darkly pigmented and the inside mucosa was greenish in color. An abrasion measuring 5x2 cm was visible at the back of the trunk.

Figure 1: Corrosive burns over the face

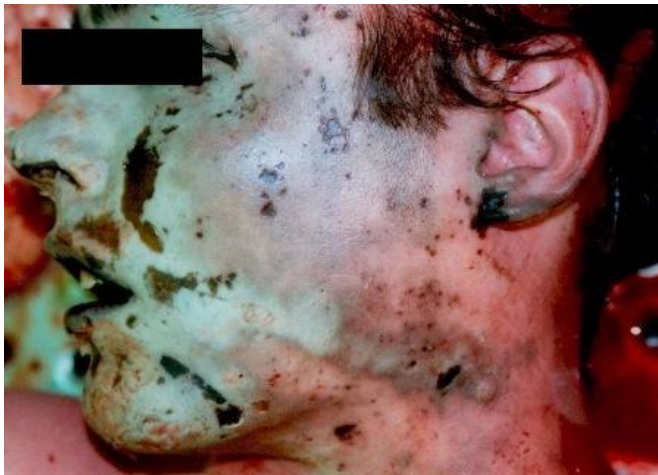
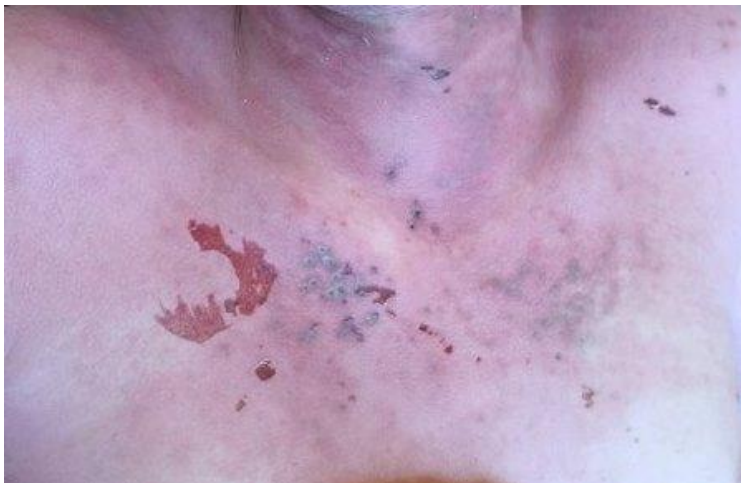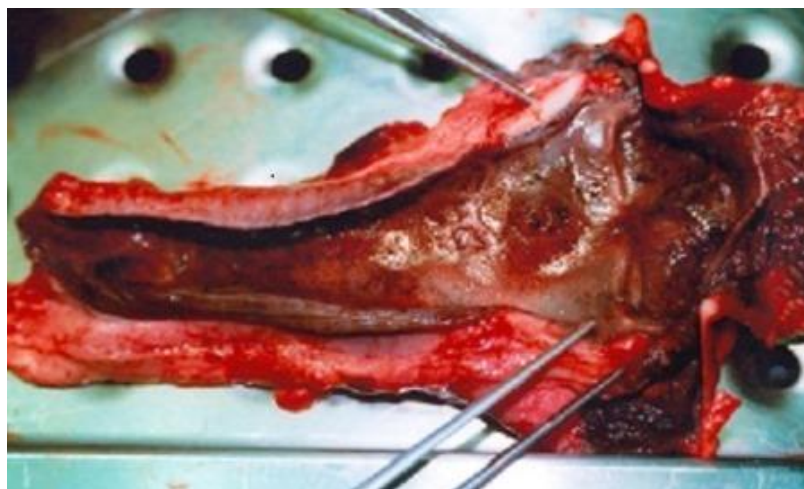


Figure 2: Corrosive, spotlike burns to the chest



The internal examination revealed a dark discoloration of the base of the tongue, epiglottis and epiglottic vallecula. The luminal surface of the trachea was brownish and greenish in color and covered with froth (Figure 3). Subpleural petechiae were visible at both lungs. The esophageal mucosa appeared intact. The stomach contained 100 mL of blood and only superficial erosions were visible on the mucosa. The rest of the findings were unremarkable.

Figure 3: The luminal surface of the trachea covered with froth and dark discoloration of the epiglottic vallecula



Histology analysis

The tissue samples of the heart, trachea, lungs, esophagus, stomach, liver, pancreas, suprarenal glands, kidneys and spleen were taken for histology examination. Paraffin-embedded tissue sections were stained with haematoxylin and eosin. The results of the histology examination are listed in Table 1.

Table 1: Histology findings

Trachea (Figure 4)	<p>Complete lack of the respiratory epithelium</p> <p>Mild subepithelial infiltration of lymphocytes and plasma cells</p> <p>Edema of the mucosa and submucosa</p> <p>Hyperemia</p> <p>Thrombi inside mucosal and submucosal small vessels</p> <p>Hemolysis and bloated erythrocytes inside vessels</p>
Lungs (Figure 5)	<p>Edematous fluid inside alveoli</p> <p>Extravasation of erythrocytes inside alveoli</p> <p>Thrombi inside small vessels</p> <p>Hemolysis and bloated erythrocytes inside vessels</p>
Esophagus	<p>Mild edema of the mucosa</p> <p>Bloated erythrocytes inside vessels</p> <p>No changes to the epithelium</p>
Stomach	<p>Mild autolysis</p> <p>Hyperemia</p> <p>Bloated erythrocytes inside vessels</p>
Liver	<p>Mild microsteatosis and macrosteatosis</p> <p>Centrolobular sinusoids dilated and filled with erythrocytes</p> <p>Sinusoides filled with bloated erythrocytes</p>
Spleen	<p>Marked expansion of red pulp</p> <p>Bloated erythrocytes</p>
Pancreas	<p>Autolysis</p>
Kidney	<p>Bloated erythrocytes inside vessels</p>
Heart	<p>Bloated erythrocytes inside vessels</p>
Suprarenal glands	<p>Bloated erythrocytes inside vessels</p>

Figure 4: Histopathological features of the trachea

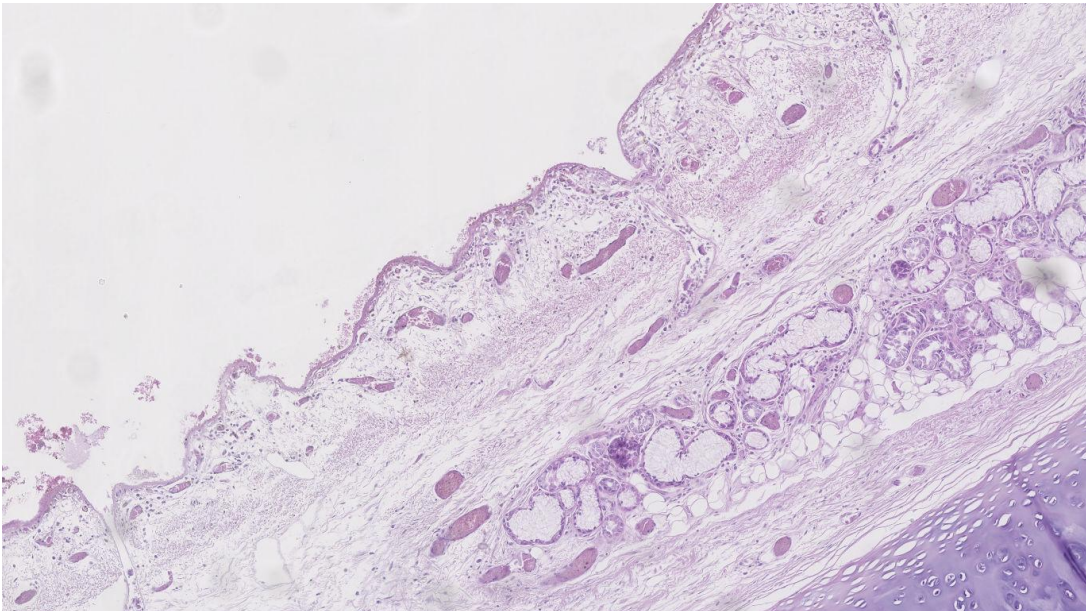
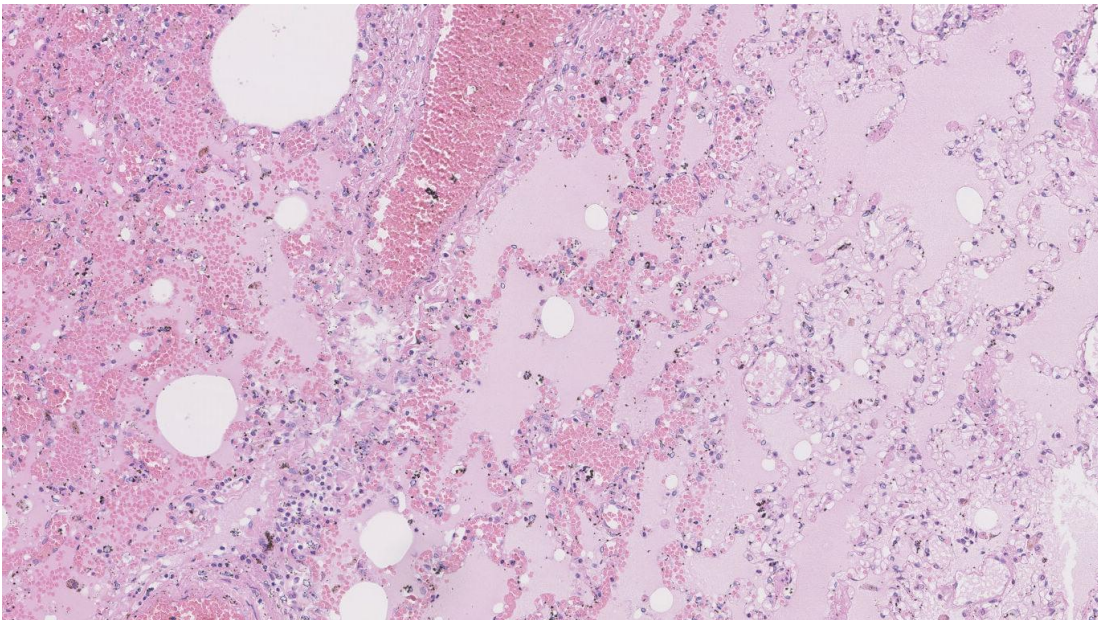


Figure 5: Histopathological features of the lungs



Toxicology analysis

Samples of the femoral blood, bile, liver, kidney, lung and gastric content were collected at the autopsy and stored at 4 °C until analysis. In addition, a plastic canister labeled "Formic acid, 85%, made by CIDA SpA Italy" was delivered by the police the next day. The plastic canister contained 0.1 L of fluid. Also, a sample of a 1 L of fluid from the plastic bucket was brought in the glass jar.

Materials and methods

Chemicals and standards

Methanol, chloroform, ethyl acetate, sodium hydroxide, barium chloride, sulfuric acid, hydrochloric acid, formic acid and *tert*-butanol were pro analysis grade and purchased from Kemika (Zagreb, Croatia). L-Cysteine BioUltra was purchased from Sigma-Aldrich (Steinheim, Germany). Polymeric adsorbent Supelco-Amberlite® XAD®-2 was purchased from Sigma-Aldrich (Bellefonte, PA, USA). Seven Easy pH meter equipped with InLab® Micro electrode was purchased from Mettler-Toledo (Schwerzenbach, Switzerland).

Sample preparation

Using pH meter, pH values were determined in dilute liquids from canister and bucket (2 %, v/v). In both of them the presence of sulphates were tested by the addition of dilute hydrochloric acid and a few drops of barium chloride solution. Quantitative determination of formic acid in the blood, bile, gastric content and tissues of liver, kidney and lung as well as diluted liquid (1:100, v/v) from 5 L PVC canister ("liquid sample 1") and diluted liquid (1:100, v/v) from PVC bucket ("liquid sample 2") was performed by measuring the methyl ester derivative of formic acid according to Abolin`s method modified by Wallage [14]. Calibrators were prepared by addition of 100 µL diluted formic acid to 500 µL of blank blood. The resulting standard concentrations were 0.05, 0.50, 1.00 and 1.50 g/L. As recommended for the case report [15] the method was partially validated. Selectivity was tested on six blank blood samples, the calibration model was tested on four calibration levels with duplicate measurements at each level, accuracy and precision were determined at low (0.10 g/L) and high (1.25 g/L) concentrations with five replicates per level.

Analysis of the blood sample for the presence of ethanol and other volatiles was performed using head-space gas chromatography with flame ionization detection (HS-GC-FID) (TurboMatrix 40, AutoSystem GC, Perkin Elmer, Shelton, CT, USA).

Carboxyhemoglobin concentration was determined by UV/Vis spectrophotometer according to Heilmeyer method [16] (LAMBDA 25 UV/Vis Systems, Perkin Elmer, Shelton, CT, USA).

The drug screen was performed by gas chromatography – mass spectrometry (GC-MS) analysis after solid phase extraction (XAD-2). The GC–MS analyses were performed using Agilent 5973N Mass Selective Detector, 6890 Gas Chromatograph and 7683 Automatic Liquid Sampler (Agilent Tehnologies, Wilmington, DE, US) equipped with an Elite–5 capillary column (25 m×0.32 mm ID, 520 nm film thicknesses) (PerkinElmerm Instruments, Shelton, US).

HS-GC-FID analysis

Quantitative formic acid analysis was performed using the TurboMatrix 40 headspace sampler and AutoSystem gas chromatograph with flame ionization detector (Perkin Elmer, Shelton, CT, USA). GC was equipped with packed column 15% Hallcomid M-18, Chromosorb W-HP 80/100 Mesch. The analyses were performed under the following condition: GC oven temperature 60 °C, injector temperature 120 °C, detector temperature 200 °C and carrier flow (N₂) 4 mL/min. The samples were thermostated in the headspace oven at 60 °C for 20 min, pressurized for 2.5 min and 0.16 mL of the vapor sample was injected into GC column. The needle and transfer line temperatures were 100 °C and 120 °C respectively. GC cycle lasted 6 min.

Results

The pH values of the "liquid sample 1" and "liquid sample 2" were 1.93 and 0.79, respectively. This demonstrated the presence of a stronger acid in the plastic bucket ("liquid sample 2"). The addition of dilute hydrochloric acid and a few drops of barium chloride solution into the "liquid sample 1" yielded no reaction, while a white dense precipitate was formed in the "liquid sample 2". This proved the presence of sulphate ion in the "liquid sample 2".

The complete results of the toxicology analysis of samples collected at the autopsy are presented in Table 2.

Table 2: The results of the toxicology analysis of samples collected at the autopsy

Sample	Formic acid concentration (g/L or g/kg)	Drug screen	Ethanol (g/kg)	Methanol (g/kg)	COHb (%)
Blood	0.28	caffeine	N.D.	N.D.	30
Bile	0.08	propyphenazone, caffeine	n.p.	n.p.	n.p.
Liver	0.06	propyphenazone, caffeine	n.p.	n.p.	n.p.
Kidney	0.24	propyphenazone, caffeine	n.p.	n.p.	n.p.
Lung	0.55	n.p.	n.p.	n.p.	n.p.
Gastric content	0.39	caffeine	n.p.	n.p.	n.p.
Canister	800	n.p.	n.p.	n.p.	n.p.
Bucket	280	n.p.	n.p.	n.p.	n.p.

N.D. - not detected

n.p. - not performed

The selectivity of the method was tested on six post-mortem blood samples and was free of interfering signals at the retention time of the methyl formate. The calibration model was investigated in the range from 0.05 g/L up to 1.50 g/L. In the investigated concentration range linear correlation of internal standard calibration was obtained. Limit of detection (LOD) and lower limit of quantification (LLOQ) was set at the lowest calibrator. The blank blood samples were spiked with formic acid at low (0.10 g/L) and high (1.25 g/L) calibration levels with five replicates. Accuracy is expressed as a percent deviation from the accepted reference value and was within ± 5.2 %. Precision is expressed as relative standard deviation (RSD, %) and was within 7.3 %.

Discussion

Intoxication with carbon monoxide produced via chemical reaction of formic and sulphuric acid is not a common method of suicide – only four cases have been previously published [10 - 13]. All of the victims were young adult men between 21 and 35 years of age. All suicides were carried out in closed spaces (plastic bag [10], sealed closet [11], car [13], bedroom [12], and bathroom in presented case). In two cases some sort of homemade device for the production of CO was found at the scene [10, 11]. Those homemade devices gave at least some sort of protection for the first responders. On the other hand, in the case presented by Yang et al. [12] the parents of the deceased also suffered an intoxication injury due to the presence of chemicals in the enclosed space. In the presented case, the sister of the deceased stated that she felt irritating sensations in her throat and eyes but did not need medical assistance. The lack of any severe symptoms was due to the correct approach of the first responders who left the bathroom immediately and called the ambulance, and also of the medical team who carried the body outside of the house to perform CPR. The strong, pungent smell of formic acid acted as a warning, just like in case presented by Lin et al [13].

The presence of corrosive effects of acid is the feature that distinguishes our case from all previous reports. The burns on the victim's body were visible on the face, neck and chest of the deceased. One might say that the burns had a look typical for formic and sulphuric acid. The prevailing type of the burn was covering almost whole face. This was a superficial burn of greenish hue. The edges of the burned skin were mostly vague. In addition, one possible trace of leaking was visible on the border of the left side of the face and neck. The appearance of this burn implies that it was mostly produced by formic acid fumes. We find this fact as an explanation for the indistinct borders between the burned and unburned skin. Burns made by formic acid are typically colored green [2]. In addition, a trace of leaking visible on the face and neck implies that the liquid formic acid was also in direct contact with the skin. Burns produced by contact with sulphuric acid are typically grey and white at the beginning, but soon become brownish to blackish and leathery [9, 17, 18]; the borders are well defined and burns tend to involve only a limited area with the possible development of deep ulceration [2]. In some cases, sulphuric acid can even cause charring of the skin [17, 18]. Knowing that, we concluded that the

small, droplet like, dark brown and black areas sharply marked from the surrounding skin were produced by splashing of sulphuric acid.

Besides chemical burns visible at the external examination, internal injuries were present, mainly to the respiratory tract. Injury to the oropharyngeal area and trachea, pulmonary edema and subpleural petechiae were noticeable. Histology analysis (Table 1) determined a complete lack of the respiratory epithelium of the trachea, edema of mucosa and submucosa of the trachea, thrombi and hemolysis inside the small vessels of the trachea, pulmonary edema, hemolysis and thrombosis in the lung vessels. These findings are connected with formic acid injury to the tissue and the effect on the coagulation system [6, 19, 20]. On the other hand, there were no significant injuries to the gastrointestinal tract. These morphological findings implied that the main route of exposure was the inhalation of formic acid fumes, while the sparing of the digestive tract speaks that no substantial ingestion of the acid took place.

Visible injuries were accompanied by the presence of formic acid in various samples. Measured concentrations are presented in Table 2. The toxic and lethal concentrations of formic acid in blood and tissue have not yet been established. This is most likely due to the rare incidence of such cases and rare performing of systematic toxicology analysis since most of the fatal outcomes arise after prolonged hospital treatment [19, 20]. Westphal et al. have reported concentrations measured in various samples of a deceased who ingested a decalcifying agent containing formic acid. They measured methyl ester of formic acid using head-space gas chromatography. The measured concentrations were: 0.37 g/L in blood at the admittance to the hospital and before hemodialysis; 0.86 g/L in heart blood collected at the autopsy; 2.7 g/L in gastric content; 3.0 g/L in bile; 0.44 g/kg in liver and 0.54 g/kg in kidney [6]. Previously, Verstraete et al. reported a concentration of 0.35 g/L in blood taken at the addition to the hospital from a person who drank approximately 200 mL of 50% formic acid and eventually died [21]. Concentration of formic acid in femoral blood measured in this case was somewhat lower but comparable to concentrations measured in above mentioned cases. The concentration in lung sample was by far the highest (0.55 g/kg) of measured concentrations, followed by concentration in gastric content (0.39 g/L). This concentration measured in the sample of the gastric content is considerably lower than the concentration of formic acid in gastric content reported by Westphal et al (2.7 g/L) [6]. Based on morphological findings (no lesions on the respiratory tract, extensive ulcerations and

necrosis of the gastrointestinal tract) and toxicology report (highest concentrations in gastric content and content of small intestine) they concluded that route of exposure in their case was ingestion and not the inhalation of formic acid [6]. Our morphological finding (severe injury of respiratory tract, presence of just mildly expressed erosions on gastric wall) and toxicology results (highest concentration of formic acid in the lungs) were suggestive of an inhalation of fumes as the main route of exposure with the possibility of some ingestion of liquid acid as well.

Concentrations of carboxyhemoglobin measured in the blood of the deceased in the presented cases ranged between 64 [11] and 93% [10]. Intoxication with carbon monoxide was stated as the cause of death in all of them [10 – 13]. In this presented case, the level of carboxyhemoglobin in femoral blood was 30 percent. Morphological findings and high levels of formic acid determined in toxicology analysis made us conclude that the combined toxicity of carbon monoxide and formic acid was responsible for the lethal outcome.

Concerning the survival time, we believe that no exact answer could be offered. However, the starting point for our consideration was the fact of high concentrations measured in lung tissue, gastric content and blood, as opposed to lower concentrations in other tissue samples, especially liver and bile. Such distribution indicates that no significant amount of formic acid was distributed to the tissues. Furthermore, chemical reaction between formic and sulphuric acid is very rapid, producing carbon monoxide almost instantaneously. Experimental data demonstrate that with concentrations of 3000 ppm of carbon monoxide in the air, it takes approximately 30 minutes to reach 30% of carboxyhemoglobin in the blood [22]. Histology analyses revealed complete lack of inflammatory reaction in the tissues. Initial infiltration of neutrophil granulocytes is expected to start within 20 to 30 minutes after the onset of noxious stimulus [23]. Taking all listed facts into account, we find reasonable to assume that death has occurred within 30 minutes from the exposure to the chemicals. This assumption is additionally supported by the fact that crime scene investigation was started one hour after the victim was seen alive by his sister. Within this hour, the victim was found in the bathroom, the medical emergency team was called, arrived at the scene and performed cardiopulmonary resuscitation. Only after the medical emergency team pronounced victim dead, crime scene investigators were called at the scene.

We find this case report to be a nice example of the broad spectrum of knowledge occasionally required by the forensic examiner to solve a case. In addition, it supports the need for case reports

as a means of communicating experiences encountered in forensic medical examiners practice. The fact of production of carbon monoxide via the reaction of formic and sulphuric acid is standard knowledge among chemists. However, it is not something we encounter in medical schools, during our education for medical examiner, nor is it something that can be found in forensic medicine textbooks. On the other hand, the lethality of this combination, not just as a means of suicide, but also as a possible threat for the first responders, urges us to widen the horizons of our professional thinking not just in order to solve a case, but also to educate everyone involved in the process of investigation.

FIGURE LEGEND

Fig. 1 Corrosive burns over the face

Fig. 2 Corrosive, spotlike burns to the chest

Fig. 3 The luminal surface of the trachea covered with froth and dark discoloration of the epiglottic vallecula

Fig. 4 Histopathological features of the trachea

Fig. 5 Histopathological features of the lungs

ETHICAL STANDARDS

The presented content completely complies with laws in the Croatia.

CONFLICTS OF INTEREST

The authors declare that they have no conflicts of interest.

REFERENCES

1. Anonymous (1997) Formic acid. International Programme on Chemical Safety, European Commission.
<http://www.inchem.org/documents/icsc/icsc/eics0485.htm> Accessed 23 April 2015
2. Kao DS, Hijjawi J (2012) Cold and chemical injury to the upper extremity. In: Song DH (ed) Plastic Surgery 4: Lower Extremity, Trunk and Burns, 3rd edn. Elsevier Saunders, London, New York, Oxford, St. Louis, Sydney, Toronto, pp 456-468
3. Moody AJ (1991) Methanol and formic acid toxicity: biochemical mechanisms. *Pharmacol Toxicol* 69:157-163
4. Seme MT, Summerfelt P, Henry MM, Neitz J, Eells JT (1999) Formate-induced inhibition of photoreceptor function in methanol intoxication. *J Pharmacol Exp Ther* 289:361-370
5. Anonymous (2010) Formic acid. Incident management. Chemical Hazards and Poisons Division, Health Protection Agency.
https://www.gov.uk/government/uploads/system/uploads/attachment_data/file/317447/hpa_formic_acid_incident_management_v1.pdf Accessed 23 April 2015
6. Westphal F, Rochholz G, Ritz-Timme S, Bilzer N, Schütz HW, Kaatsch HJ (2001) Fatal intoxication with a decalcifying agent containing formic acid. *Int J Legal Med* 114:181-185
7. Anonymous (2001) Sulfuric acid. UNEP publications.
<http://www.inchem.org/documents/sids/sids/7664939.pdf> Accessed 23 April 2015
8. Pritchard JD (2011) Sulphuric acid. Centre for Radiation, Chemical and Environmental Hazards, Health Protection Agency.
https://www.gov.uk/government/uploads/system/uploads/attachment_data/file/318231/HPA_Compndium_of_Chemical_Hazards_SULPHURIC_ACID_v3.pdf Accessed 23 April 2015
9. Palao R, Monge I, Ruiz M, Barret JP (2010) Chemical burns: pathophysiology and treatment. *Burns* 36:295-304. doi: 10.1016/j.burns.2009.07.009
10. Wehr K, Schäfer A (1987) [An unusual case of suicidal carbon monoxide poisoning]. *Arch Kriminol* 180:155-160
11. Prahlow JA, Doyle BW (2005) A suicide using a homemade carbon monoxide "death machine". *Am J Forensic Med Pathol* 26:177-180
12. Yang CC, Ger J, Li CF (2008) Formic acid: a rare but deadly source of carbon monoxide poisoning. *Clin Toxicol (Phila)* 46:287-289. doi: 10.1080/15563650701378746

13. Lin PT, Dunn WA (2014) Suicidal carbon monoxide poisoning by combining formic acid and sulfuric acid within a confined space. *J Forensic Sci* 59:271-3. doi: 10.1111/1556-4029.12297
14. Wallage HR, Watterson JH (2008) Formic Acid and Methanol Concentrations in Death Investigations. *J Anal Toxicol* 32:241-247
15. Peters FT, Drummer OH, Musshoff F (2007) Validation of new methods. *Forensic Sci Int* 165:216-224
16. Heilmeyer L (1933) Das Kohlendioxid-Haemoglobin. In: Heilmeyer L (ed) *Medizinische Spektrophotometrie*, Gustav-Fischer-Verlag, Jena, pp 86-92
17. Saukko P, Knight B (2004) Corrosive and metallic poisoning. In: Saukko P, Knight B (eds) *Knight's Forensic Pathology*, 3rd edn. Arnold Publications, London, pp 585-594
18. Bardale R (2011) Corrosive poisons. In: Bardale R (ed) *Principles of Forensic Medicine and Toxicology*, Jaypee brothers medical publishers (P) LTD, New Delhi, Panama city, London, pp 437-444
19. Naik RB, Stephens WP, Wilson DJ, Walker A, Lee HA (1980) Ingestion of formic acid-containing agents - report of three fatal cases. *Postgrad Med J* 56: 451-456
20. Rajan N, Rahim R, Krishna Kumar S (1985) Formic acid poisoning with suicidal intent: a report of 53 cases. *Postgrad Med J* 61:35-36
21. Verstraete AG, Vogelaers DP, van den Bogaerde JF, Colardyn FA, Ackerman CM, Buylaert WA (1989) Formic acid poisoning: case report and in vitro study of the hemolytic activity. *Am J Emerg Med* 7:286-290
22. Forbes WH, Sargent F, Roughton FJW (1945) The rate of carbon monoxide uptake by normal men. *Am J Physiol* 143:594-608
23. Madea B, Grellner W, Kondo T (2014) Vital Reactions and Wound Age Estimation. In: Madea B (ed) *Handbook of Forensic Medicine*, Wiley-Blackwell, Chichester, pp 237-253